International Journal of BioMedicine 3(2) (2013) 78-80

INTERNATIONAL JOURNAL OF BIOMEDICINE

CLINICAL RESEARCH

Efficiency of Stereotactic Conformal Radiotherapy in Lung Metastases with Active Breathing Control

Olga Yu. Anikeeva, PhD, Oxana A. Pashkovskaya*, Petr V. Filatov, Elena A. Samoilova, PhD

Federal State Institute "Academician E.N. Meshalkin Novosibirsk State Research Institute of Circulation Pathology", Novosibirsk, Russian Federation

Abstract

Twenty four patients with lung metastases underwent radiosurgery treatment between October 2010 and December 2012. Stereotactic conformal high-dose radiation therapy with Active Breathing Control (ABC) was conducted using the volumetric modulated arc therapy (VMAT) technique.

The median overall follow-up was 18 months (range 6-24 months), overall survival was 75%, and local control rate was 92%. The median time to progression was 4 months (range 1-18 months).There have been no cases of leucopenia, radiation esophagitis, mediastinitis or severe acute radiation pneumonitis. *The* late radiation effects Grade 2, according to the LENT SOMA scales, was observed in one patient (4%). The results of this study indicate that the usage of the stereotactic high-dose radiation therapy with ABC is safe and effective in the treatment of lung metastases.

Keywords: *radiosurgery, stereotactic conformal radiotherapy, lung metastases, active breathing control.*

Introduction

The lungs are one of the most common sites for metastatic (secondary) lesions due to the presence of an extensive capillary network. Also, the lungs are the first organs, through which the venous blood passes after flowing into the vein of the greatest lymphatic vessels. Usually, the frequency and nature of the metastatic disease depend upon the localization of the primary tumor. In 6-30% cases it is the insulated metastatic lesions that get affected [1]. In about one-third of patients with insulated lung lesions, isolated pulmonary metastases are observed, which are located in the lung periphery [2] and are amenable to surgical or combined modality treatments. The current approaches of the treatment include both radiation therapy and radiosurgery, which enable us to achieve not only a partial response, but also a prolonged remission [3]. Thus, metastatic dissemination in the lungs does not imply incurability in the cancer patients. The peripheral pulmonary tissue, according to radiobiological models, is a parallel structure. High radiation doses can be delivered to the metastases without any excessive risk of lung pulmonitis, assuming only a small volume of lung is subjected to irradiation.

Hyperfractionated radiation therapy is a procedure that has been clinically tested in escalation dose studies [4-6]. Patients with inoperable non-small cell lung cancer (NSCLC), T1 stage, were included in these studies. Researchers from Colorado University report that the maximal tolerable dose can be safely escalated from 48 to 60 Gy, delivered in 3 fractions [5]. In phase II of the study, 60 Gy was the dose given [5]. This dose enabled obtaining 100% and 96% of actuarial local control at one and two years, respectively. Similar results were achieved in other studies by giving high-dose radiation to patients with NSCLC, T1 stage [4,6]. The response was observed to be dose-dependent and the local control rates improved with increasing doses of radiation.

The objective of this study was the estimation of the efficiency and tolerability of the high-dose stereotactic radiation therapy using the ABC in patients with isolated pulmonary lung metastasis.

Material and Methods

Twenty four patients (15 men and 9 women) with isolated pulmonary metastasis in the lung underwent hypofractionated stereotactic conformal radiation therapy. The mean age was 65.5 years (range 52-79 years). Patients were treated in the Center

***Corresponding author**: Oxana A. Pashkovskaya. Center for radiosurgery and radiotherapy of Federal State Institute "Academician E.N. Meshalkin Novosibirsk State Research Institute of Circulation Pathology". 15, Rechkunovskaya st, Novosibirsk, 630058, Russian Federation. Tel: +79134882545 E-mail: oxana.pashkovskaya@gmail.com*

of Radiosurgery and Radiotherapy of the Meshalkin Research Institute of Circulation Pathology (Novosibirsk, Russia) between October 2010 and December 2012. The characteristics, morphology and primary tumor sites of metastases of the patients are summarized in Table 1.

Table 1.

Patients' characteristics, morphology and the primary tumor sites of metastases

Patients' characteristics	Patients (n = 24)
Men	15 (62.5 %)
Women	9 (37.5 %)
Average age, yrs	65.5
Co-morbidity	98%
Performance	
ECOG WHO	1— 8 %, 2— 36 %, 3— 56 %
Smoking	
Not once	5 (20.8 %)
Former smokers	14 (58.4 %)
Current smokers	5 (20.8 %)
Morphology	
Squamous cell cancer	5 (20.8 %)
adenocarcinoma	18 (75 %)
—high-grade	2
— moderate-grade	9
— low-grade	6
— poorly	1
Clear cell carcinoma	1 (4.2 %)
Colon cancer	6 (27.7 %)
Breast cancer	8 (33.3 %)
Lung cancer	6 (22.2 %)
Ovary cancer	3 (11.1 %)
Endometrial stromal sarcoma	1 (5.5 %)

Inclusion criteria included age older than 18 years, patients with isolated pulmonary metastases in the lung periphery from any primary site, except leukemia and lymphoma, maximum diameter of metastases less than 70 mm; no prior radiation therapy in the past, sufficient lung performance (sustained arterial oxygen saturation more than 90% with minimal exercise stress, forced expiration volume in one second (FEV1) greater than 40% of the expected value, diffusing lung capacity more than 40% of the expected value); the absence of systemic therapy for two weeks prior and post irradiation, permitting the small tumors outside the lungs; Karnofsky performance status (KRS) greater or equal to 70%.

The exclusion criteria were disease progression, bleeding threat, evident radioreaction (hyperthermia, acute agranulocytosis), lack of set-up reproducibility due to insufficient ABC tolerance, and other contradictions to radiation treatments.

Tumor response was estimated on contrasted-CT images through 3, 6, 12, 18, and 24 months post treatment or otherwise if indicated. The local control rate was independently assessed from a distant progression through six months. This type of follow-up period was chosen to exclude the early side effects and metabolic changes in the irradiated tissue [7,8].

All the patients were positioned supine on the table, with their arms above their heads. The ABC device was used to immobilize the lung during the CT session and treatment. Contrast (Omnipaque™) scans were acquired employing the Aquilion LB CT scanner (Toshiba Medical Systems, Tokyo, Japan), using 2 mm slice thickness. The CT images were transferred to the FocalPro station (Elekta Instruments AB) for targets and organs at risk (OAR) delineation. Dose planning was done utilizing ERGO++ treatment planning system (TPS) (Elekta Instruments AB). The target volumes were defined according to ICRU 50 [9]. The gross tumor volume (GTV) was the visible tumor. The clinical target volume (CTV) was generated to account for microscopic invasion by 10 mm expansion of the GTV. The planning target volume (PTV) was generated to account for set-up inaccuracy and organ motion by 5 mm for the upper and middle lobes and 7 mm for the lower lobe of the lung expansion of the CTV. The treatment technique involved volumetric modulated arc therapy (VMAT). Prior to each treatment, all the patients received CBCT scans with ABC [10]. The tumor and critical positioning of structures were analyzed with Elekta X-ray volume imaging (XVI) software. Automated 3D registration of the reference CT planning scan and the XVI scans was performed using the cross-correlation algorithm [11] provided in the Elekta XVI software.

The tumors were treated with a dose of 45-60 Gy, whilst the fraction dose was 15-20 Gy. The volume of the tumors and localization of the critical organs defined the fraction and overall doses. Radiation exposure to the critical organs (mediastinum, spinal cord, oesophagus, other lung, and liver) was estimated considering the tolerance levels of the normal adjacent tissues. The irradiation sessions were arranged every other day, and in exceptional cases every 3-5 days.

Results

Tumor response estimations, post radiation treatment, were met with for 23 patients. No monitoring of the CT scans for the others was done; however, their treatment outcomes were decided on X-ray image evaluations and overall survival.

Tumor regression (complete, partial, stable disease) based on CT image evaluation was 92%. Tumor parameters and irradiation doses are presented in Table 2.

Table 2.

Tumor characteristics and fraction schemes

Characteristics	%
Tumor	
Peripheral	19 (90 %)
Central	5 (10 %)
An average diameter	36 ± 11mm
Volume	15.1 см^3 (4.8–78 sm^3)
Delivered dose (BED)	
48 Gy/3 fr (105.6 Gy)	4(16.6 %)
54 Gy/3 fr (151.2 Gy)	14 (58.3 %)
60 Gy/3 fr (150 Gy)	2 (11.1 %)
20 Gy/1 fr (60 Gy)	4 (22.2 %)

Note: BED - biological effective dose.

The median overall follow-up was 18 months (range 6-24 months). The overall survival was 75% (18 patients) and the local control rate was 92%. The median time to progression

was four months (range 1-18 months) from the beginning of the radiosurgery. Figure 1 represents the CT images of the typical patients before and after irradiation.

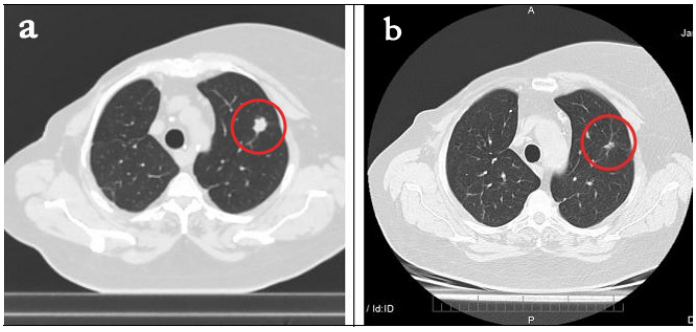

Figure 1.

The typical patient (age 57 years) with the isolated metastasis in the upper lobe of the left lung. Breast cancer, T2N1M1. Patient underwent high-dose radiation therapy: 54 Gy/3 fr. a) before treatment, b) 7 months after treatment. The complete response of the lesion can be seen.

Discussion

The first signs of progression were the distant metastases in 5 patients and the local recurrence in 2 patients. With 23 patients enrolled in this CT image evaluation, the complete response was 13% (3 patients), with 39.1% (9 patients) achieving a complete response, stable disease was found in 17.4% cases (4 patients) and 30.5% (7 patients) revealed progression of the disease. Five patients died by the end of the follow-up period, progression disease being the cause of death in three patients (local recurrence occurred in one patient, one case had several liver metastases found on CT images eight months after irradiation and one patient had metastases in the central nervous system (CNS)). One patient died due to a repeated heart attack through six months after irradiation, one patient had a spreading colon cancer. In one case, a patient with advanced breast cancer had stable disease over metastatic lung disease more than 12 months after irradiation, although radiosurgery of the CNS metastases was required. It should be noted, that no incidence of grade 3 or higher acute toxicity (RTOG scale) associated with irradiation were encountered in any of our patients. There have been no cases of leucopenia, radiation esophagitis, mediastinitis or severe acute radiation pneumonitis. *The* late radiation effects Grade 2, according to the LENT SOMA scales, was observed in one patient. This proves that radiosurgery for lung metastases provides excellent local control rates, *rivaling* those found in the studies of *surgical* management (the usual treatment of choice) for lung metastases [12]. Therefore, radiosurgery treatment may be the real alternative to tumor resection in patients with small lung metastases. The typical requirements for hyperfractionated radiation therapy include the largest diameter and the volume of the lesion not exceeding 70 mm and volume 15 cm^3, respectively.

Conclusion

The results of this study indicate that the usage of the stereotactic high-dose radiation therapy with ABC is safe and effective in the treatment of lung metastases. Further studies are suggested to define the optimal dose and evaluate the advantages and disadvantages of the various treatment schedules.

References

1. Ricardi U, Filippi AR, Guarneri A, Ragona R, Mantovani C, Giglioli F, et al. Stereotactic body radiation therapy for lung metastases. Lung Cancer 2012; 75(1):77-81.

2. Wulf J, Haedinger U, Oppitz U, Thiele W, Mueller G, Flentje M. Stereotactic radiotherapy for primary lung cancer and pulmonary metastases: a noninvasive treatment approach in medically inoperable patients. Int J Radiat Oncol Biol Phys 2004; 60(1):186-96.

3. Abratt RP, Bogart JA, Hunter A. Hypofractionated irradiation for non-small cell lung cancer. Lung Cancer 2002; 36(3):225-33.

4. Brown WT, Wu X, Wen BC, Fowler JF, Fayad F, Amendola BE, et al. Early results of CyberKnife image-guided robotic stereotactic radiosurgery for treatment of lung tumors. Comput Aided Surg 2007; 12(5):253-61.

5. Rusthoven KE, Kavanagh BD, Burri SH, Chen C, Cardenes H, Chidel MA, et al. Multi-institutional phase I/II trial of stereotactic body radiation therapy for lung metastases. J Clin Oncol 2009; 27(10):1579–84.

6. Brock J, Ashley S, Bedford J, Nioutsikou E, Partridge M, Brada M. Review of hypofractionated small volume radiotherapy for early-stage non-small cell lung cancer. Clin Oncol (R Coll Radiol) 2008; 20(9):666-76.

7. Schefter TE, Kavanagh BD, Raben D, Kane M, Chen C, Stuhr K, et al. A phase I/II trial of stereotactic body radiation therapy (SBRT) for lung metastases: Initial report of dose escalation and early toxicity. Int J Radiat Oncol Biol Phys 2006; 66:120–7.

8. Timmerman R, McGarry R, Yiannoutsos C, Papiez L, Tudor K, DeLuca J, et al. Excessive toxicity when treating central tumors in a phase II study of stereotactic body radiation therapy for medically inoperable early-stage lung cancer. J Clin Oncol 2006; 24(30):4833-9.

9. Giraud P, Yorke E, Ford EC, Wagman R, Mageras GS, Amols H, et al. Reduction of organ motion in lung tumors with respiratory gating. Lung Cancer 2006; 51(1):41-51.

10. International Commission on Radiation Units and Measurements. ICRU report 50. Prescribing, recording, and reporting photon beam therapy. Bethesda, MD: International Commission on Radiation Units and Measurements; 1993.

11. Hristov DH, Fallone BG. A grey-level image alignment algorithm for registration of portal images and digitally reconstructed radiographs. Med Phys 1996; 23(1):75–84.

12. Vodicka J, Spidlen V, Simanek V, Safranek J, Skalicky T, Fichtl J, et al. Surgical therapy of pulmonary metastases - 10-year results. Bratisl Lek Listy 2013; 114(4):218-24.