International Journal of BioMedicine 4(4) (2014) 237-241

INTERNATIONAL JOURNAL OF BIOMEDICINE

PROBLEMS OF PEDIATRICS

Treatment of Lymphatic Malformations with OK-432: the First Experience of a Single Hospital

Iryna Benzar

Department of Pediatric Surgery, Bogomolets National Medical University Kyiv, Ukraine

Abstract

Purpose: This study aims to evaluate the effectiveness of OK-432 immunotherapy in the treatment of lymphatic malformation (LM) in children and to determine its complications and contraindications.

Methods: Twenty-eight patients with LM of head and neck were enrolled. Twenty-three (82.2%) patients were treated with OK-432 immunotherapy, and surgery was performed in 5 (17.8%). LMs were classified as macrocystic, microcystic, or combined, and according to de Serres clinical stages. OK-432 immunotherapy consisted of a puncture, aspiration and intralesional injection of OK-432.

Results: Three patients with contraindication to OK-432 were successfully treated surgically. In patients with parotid involvement recurrence of LM and facial nerve branch, paresis occurred. After OK-432 treatment and a single session of 1 KE of OK-432, favorable results were obtained in patients with stage I and macrocystic lesions. In patients with stage III, the result was excellent or good in 7 (70%) and fair in 3 (30%). We didn't receive satisfactory results in groups IV and V (good – 1, fair – 4, poor – 1).

Conclusion: OK-432 immunotherapy is safe, effective, and simple to use. The result of treatment depends on cystic size, extent of lesions, and previous interventions, and was most successful in unilateral macrocystic LM.

Keywords: *Lymphatic Malformation, OK-432, sclerotherapy.*

Introduction

The reported incidence of lymphatic malformation (LM) is from 1 in 2000 to 1 in 16000 live births [1,2]. Although surgery is considered the mainstay of treatment [3], complete excision is frequently impossible owing to the risk of damage to vital structures and such future complications as nerve injury, recurrence, bleeding, and cosmetic defects. During the past 30 years, sclerotherapy has emerged as a promising alternative to surgical management for LMs in children with most commonly studied sclerotherapy agent OK-432 [4]. In 1987, S. Ogita et al first reported that OK-432 (Chugai Pharmaceutical Co., Tokyo, Japan) is a safe and effective therapy in the management of LM in children and adults [5]. A number of small studies [4] and a single randomized multicenter trial [6] confirm these observations.

The main advantages of OK-432 compared with other sclerosants, such as ethanol or bleomycin, is a lack of major complications and absence of perilesional fibrosis, which allows for subsequent surgery in cases of treatment failure [7].

Furthermore, OK-432 is widely used internationally; in Ukraine it has been available since 2011. A relatively small number of patients have been treated in Eastern Europe [4]. Therefore, we thought it important to report our first experience of this treatment method comprising patients only from Ukraine in one medical center.

Methods

This prospective study included 28 children with cervicofacial LM admitted to the hospital from January 2011 to January 2013. Patients with a follow up of less than 6 months, those with lesions involving the thorax, retroperitoneal space or an extremity, and subjects lost to follow up were excluded from this study. Written informed consent was obtained from the child's parents.

Symptoms were present at birth in 20 (71.4%) children, 8 (40%) of which were diagnosed prenatally by a routine ultrasound (US) examination. The remaining LMs manifested clinically during the first 2 years of life in 5 (17.8%) patients

***Corresponding author:** *Iryna Benzar. Department of Pediatric Surgery, Bogomolets National Medical University, Kyiv, Ukraine. E-mail: ira_benzar@yahoo.com*

and after 2 years in only 3 (10.7%) cases.

Symptoms included visible nontender swellings with cosmetic concerns, tongue protrusion (n=2), speech difficulties (n=3), dysphagia (n=2), dental problems (n=4), recurrent infection (n=1), and recurrent intralesional bleeding (n=4). The most difficult complication was respiratory failure due to upper airway obstruction in 2 patients. Tracheostomy was performed before OK-432 treatment in both clinical cases.

Surgery was performed in 5 (17.8%) children. Indications for operative excision were recurrent inflammation (n=1), massive bleeding in the cyst that makes it impossible to differentiate lymphatic and venous malformation (n=3), and an allergic reaction to penicillin in history (n=1).

Twenty-three patients were treated with OK-432 immunotherapy. The mean age at the time of the first injection was 3 years and 4 months (range 6 month to 16 years). Ten children were under 1 year of life, 5 were from 1 to 3 years old, and 8 were over 3 years.

LMs were classified as macrocystic, microcystic, or mixed (macrocystic-microcystic), which has proven useful in other sclerotherapy studies [2,6]. Classification was determined radiographically by MRI and ultrasound (US) examination. We used the US examination without MRI in three cases of superficial, well-localized cervical LMs. Macrocystic LM was defined as an LM comprising 1 or more cysts, all of which were greater than 2 cubic centimeters (cc) in volume; microcystic LMs were defined as LM comprising multiple cysts, all of which were less than 2 cc in volume. An LM with microcystic components more than 50% was defined as a mixed LM.

To evaluate the response to treatment depending on localization and extent of lesion, we used the de Serres staging system [8]. Stage I: unilateral infrahyoid disease; stage II: unilateral suprahyoid disease; stage III: unilateral suprahyoid and infrahyoid disease; stage IV: bilateral suprahyoid disease; stage V bilateral suprahyoid and infrahyoid disease.

Laboratory studies (white blood cell count, hematocrit, platelet count, erythrocyte sedimentation rate (ESR), C-reactive protein, blood urea-nitrogen, serum creatinine, alkaline phosphatase, aspartate aminotransferase, (AST), alanine aminotransferase (ALT), and bilirubin levels), urinalysis, and electrocardiogram were recorded and analyzed before each session. In two patients with solid masses and unclear diagnoses, we performed a preoperative biopsy.

Each procedure was done in the operating room under general anesthesia in young children, aged 6 months to 9 years, or under local anesthesia in a 16-year-old girl. We used real-time ultrasound guidance, if needed, to assist with cyst localization. A solution of OK-432 was prepared by dissolving 1 KE of OK-432 in 2–10 cc of isotonic sodium chloride solution. The volume of solvent depended on the cyst's size. After aspirating as much fluid as possible and taking care not to dislodge the catheter, OK-432 was injected. The maximum dose injected at one treatment session was 2 KE. The interval between sessions ranged from 2 to 6 months; the average was 4.2 months. Aspirated fluid was analyzed on the cell population.

Response to OK-432 immunotherapy was assessed clinically and recorded radiologically as a percentage reduction in volume and graded as excellent (90%–100% reduction in volume), good (60%–89% reduction in volume), fair (20%–59% reduction in volume), or poor (0%–19% reduction in volume). This categorization was based on a similar classification system published in recent references in this area [1,4,6]. Follow-up ranged from 6 months to 2 years.

Results

2.1. Surgery

Before 2011, all patients with LM were treated surgically. Since OK-432 sclerotherapy was introduced as a therapeutic option in our clinic, surgery is the treatment of choice for patients with contraindications for OK-432 immunotherapy and was performed in 5 (17.8%) children with LM of head and neck.

In 4 patients from the surgery group, the LM was confined to the neck, well localized and was successfully removed in a single operation. One patient, an 8-month-old girl, had parotid involvement and needed a second operation due to recurrence. In addition, this patient had facial nerve branch temporary paresis in the postoperative period.

2.2. OK-432 immunotherapy

The patients' characteristics and results of the treatment are summarized in Table 1.

OK-432 immunotherapy was done as a first line treatment in 18 (78.3%) children. Previous surgical resection had been performed in 4 patients; one of them had multiple operations (case 5), and one child had previously undergone cryodestruction, ablation, and systemic corticosteroids treatment (case 6)..

In the aspirated fluid, the white blood cells and single red blood cells usually revealed, 94±4.3% white blood cells were lymphocytes, and the remaining were neutrophils and macrophages. In one clinical case, atypical cells were found. Treatment was stopped and a biopsy performed. Histological investigation diagnosed embryonic cancer. The child was successfully treated by chemotherapy. This patient was excluded from the study.

The expected general response to OK-432 immunotherapy included fever (3-5 day), refusal to eat (1- 3 days), and malaise, local inflammatory reaction included edema with pain (from 3 days to 6 weeks), erythema (2-3 days), bruise. Patients and their families completed study diaries documenting temperature, pain, erythema, edema, and side effects (limitation of extremities movement, respiratory failure etc.) daily for 14 days after the session, and then once a week. Major adverse events related to OK-432 immunotherapy included re-hospitalization for severe edema that led to fluid aspiration (n=2) and skin allergic reaction (n=1). The next session was performed if a residual cyst was found and there weren't any general and local signs of inflammation. Before each injection session blood analysis and US of lesion is mandatory. Suspended matter and/or strands of fibrin in the cyst revealed during US scanning are the signs of persistent inflammation.

Table 1.
Consecutive patients treated with OK-432

Case number	Debut of symptoms	Age at first session	Clinical stage	Cystic size	Previous procedure	Session's number (n)	Total dose of OK-432	Result
1.	Newborn	10 month	V	Combined	None	4	4 KE	Good
2.	5 year	16 year	I	Combined	Surgery, age 8 year	2	2 KE	Good
3.	Newborn	8 month	III	Combined	None	5	6 KE	Good
4.	Newborn	6 month	III	Combined	None	3	3 KE	Fair
5.	Newborn	8 month	V	Microcystic	Surgery, age 1 and 4 month, tracheostomy	4	6 KE	Fair
6.	Newborn	1 year 6 month	IV	Microcystic	Cryodestruction, ablation, systemic corticosteroids	3	3 KE	Poor
7.	Newborn	9 month	III	Macrocystic	None	2	2 KE	Excellent
8.	4 year 5 month	4 year 7 month	III	Macrocystic	None	1	1 KE	Excellent
9.	Newborn	1 year 4 month	I	Macrocystic	None	1	1 KE	Excellent
10.	Newborn	10 month	III	Combined	None	4	5 KE	Excellent
11.	Newborn	10 month	III	Combined	None	2	2 KE	Fair
12.	Newborn	2 year 4 month	III	Macrocystic	None	2	2 KE	Good
13.	Newborn	5 year	IV	Microcystic	Surgery, age 3 year	2	3 KE	Fair
14.	Newborn	2 year 6 month	III	Macrocystic	None	1	1 KE	Excellent
15.	Newborn	7 month	I	Macrocystic	None	1	1 KE	Excellent
16.	Newborn	10 month	I	Macrocystic	Surgery, age 7 month	2	2 KE	Excellent
17.	Newborn	5 year	III	Macrocystic	Surgery, age 3 year	1	1 KE	Fair
18.	Newborn	7 year	IV	Microcystic	None	2	2 KE	Fair
19.	3 year	5 year	I	Macrocystic	None	1	1 KE	Excellent
20.	1 year 6 month	1 year 8 month	I	Macrocystic	None	1	1 KE	Excellent
21.	3 month	9 year	III	Combined	None	1	1 KE	Good
22.	Newborn	8 year	I	Macrocystic	None	1	1 KE	Excellent
23.	Newborn	6 month	V	Combined	Tracheostomy	4	5 KE	Fair

Patients with stage I according to the de Serres classification and macrocystic LM (n=5) had an excellent result in all cases after a single injection session of OK-432 in dose 1KE (Fig.1). Two children who were treated previously needed the second session of OK-432 sclerotherapy; the general dose was 2 KE. An excellent result was achieved in the case of macrocystic form and a good result in patients with combined LM.

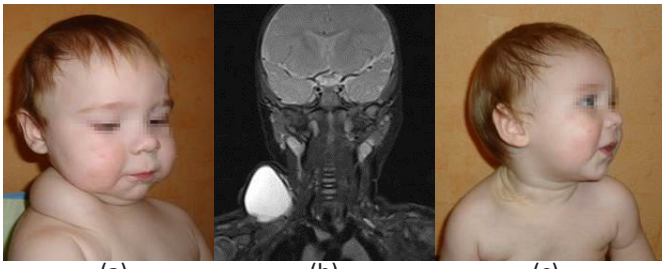

(a) (b) (c)

Figure 1.
Complete absorption of macrocystic LM after a single OK-432 intralesional injection: (a) patient's photo, (b) coronal T2-weighted image before treatment, (c) patient's photo 12 month after treatment.

Stage III was found in 10 children, 5 of the LMs were defined as combined and 5 as macrocystic lesions, including 1 patient after previous surgical incision. In patients with the combined form of LM, the mean number of sessions was 3 (range 1- 5 injections); the mean dose of OK-432 was 3.4 KE (range 1-6 KE). In cases of macrocystic LM, 1 (n=3) or 2 (n=2) sessions were performed; the mean dose of OK-432 was 1.4 KE. Excellent and good results were achieved in 3 patients with combined lesions and in 4 patients with the macrocystic form (Fig.2). The result was fair in 2 cases of combined LM and in 1 child with macrocystic LM.

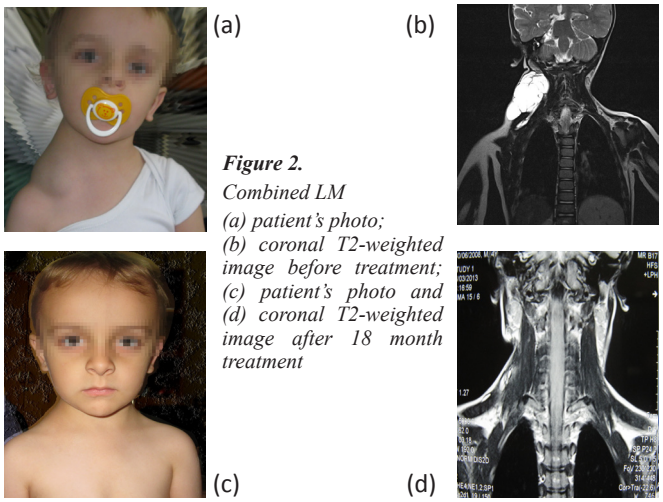

(a) (b) (c) (d)

Figure 2.
Combined LM
(a) patient's photo; (b) coronal T2-weighted image before treatment; (c) patient's photo and (d) coronal T2-weighted image after 18 month treatment

Three patients had clinical stage IV of LM; all cases were microcystic forms. Only one child received OK-432 as a first line treatment, one patient had been treated previously surgically, and another child had multiple procedures of cryodestruction, ablation, and systemic corticosteroids. We didn't receive satisfactory results in this group: in 2 patients the result was fair, and in 1 case it was poor (Fig.3).

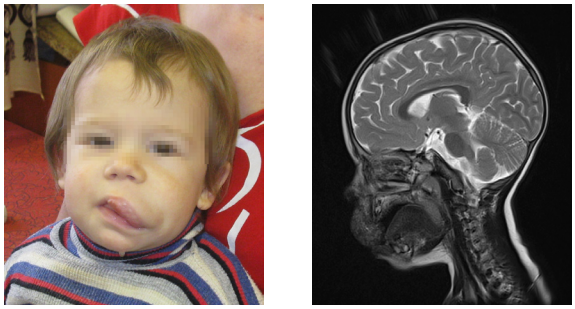

(a) (b)

Figure 3. *Poor result in 3-year old boy with microcystic LM after three sessions of OK-432 immunotherapy and previous multiple procedures: (a) patient's photo , (b) sagital T2-weighted image.*

Clinical stage V was diagnosed in 3 clinical cases. In all patients, 4 sessions of OK-432 were done; a general dose of OK-432 ranged from 4 to 6 KE, the mean dose being 5 KE. A good result was achieved in one patient with the combined form of lesions. In patients with recurrent LM after surgical excision and in patients with a very large lesion, the result was fair.

After a follow-up period of from 6 months to 2 years after the last session of OK-432 immunotherapy, there have been no recurrences.

Discussion

In the past, LMs were approached as neoplasms; hence, the terms *lymphangioma* and *cystic hygroma*. Since 1982, when Mulliken and Glowacki introduced the biological classification, these lesions have been clearly in the spectrum of vascular malformations [9]. In 1996, the ISSVA arrived at a Mulliken-based nosological consensus that forms the current vascular anomaly classification framework [10].

LMs demonstrate endothelial monolayer-lined small or microscopic channels (microcystic) or enlarged spaces (macrocystic) that contain few lymphocytes, proteinaceous fluid, and even erythrocytes [11].

LMs are usually noted at birth, or even diagnosed prenatally by fetal ultrasonography, and 90% become clinically apparent by the age of 2 years; others can be seen at any age [1,4]. In our study, 89.3% of LMs are present before the age of 2 years, and 28.6% are diagnosed prenatally.

LM can occur anywhere on the body, and symptoms are determined by the extent of the disease. Approximately 75% of LMs are found in the cervicofacial region. In these patients, involvement of the upper aerodigestive tract can cause a significant functional compromise that is difficult to treat [3]. Some patients need a tracheosotomy, which is a clinical and social problem.

The clinical course of the pathology varies from a spontaneously regressing cyst to an aggressively invasive lesion. Some references noted spontaneous regression of LMs [2], but we didn't see any case of spontaneous regression after 6 months of observation.

The correct radiological diagnosis is essential in order to decide the most appropriate treatment for the patient. MRI is the preferred imaging modality for diagnosis, and for assessing the lesions' extension and their relationships to adjacent structures [12].

Fine needle aspiration is not recommended routinely because the yield is minimal and because it poses a risk of secondary infection [2]. In cases with an uncertain diagnosis we prefer additional investigation, including biopsy.

From mild cosmetic deformity to life-threatening airway obstruction, these malformations have myriad clinical presentations, and there are multiple classification schemes for LMs. The clinical picture and response to therapy of LM of the head and neck are related to the size and anatomical location of the lesion and unilateral or bilateral involvement. In 1995, de Serres proposed the staging system based on a progression of extent of disease. In this study, the postoperative complication rate after surgical excision of LMs increased from 17% in stage I to 100% in stage V [8].

An ideal option for treatment of LM does not exist. Overall, treatment for LM should be aimed at complete elimination of the disease. When this is not feasible, multiple treatment modalities are combined to control disease and provide satisfactory functional outcomes [3,13].

The most widely accepted therapy has been surgery, but complete resection is rarely possible and the possibility of scarring and damage to surrounding structures exists [6,12]. Among alternative methods, sclerotherapy is the most widely explored.

First used in 1987 and now most commonly used, OK-432 (Chugai Pharmaceuticals, Tokyo, Japan) is a lyophilized powder of *Streptococcus pyogenes* (group A, type 3, Su strain) incubated with benzylpenicillin. OK-432 isn't exactly a sclerosing agent, because it doesn't destroy the vascular endothelium. OK-432 induces apoptosis of the lymphatic endothelium and a local cellular inflammatory reaction [5,14]. Recent studies have demonstrated that the pathway of action of OK-432 within lymphangiomas is probably cellular and cytokine-mediated. S. Ogita et al [15] evaluated the immunological changes in lymphangioma fluid after OK-432 injection in 6 patients and detected a significant inflammatory migration into the cyst fluid. S. Wiegand et al [16] found rising IL-6 levels during treatment, resulting in an approximately 25-fold increase in IL-6 after repeated OK-432 injection.

The initial and long-term response rates after OK-432 immunotherapy were equally good for LM: initial response rate was 83.5% and long-term response rate was 76.3% [17].

All published results show that patients with macrocystic LMs after OK-432 immunotherapy have a significantly better treatment outcome compared with patients with mixed or microcystic lesions. Of note, total lesion volume was not predictive of a successful response. Disease location had a major influence on prognosis, with isolated neck disease

having the highest likelihood of complete resolution regardless of treatment modality. Patients with stage I, II, or III disease had a significantly better clinical response to therapy than did those with stage IV or V disease [14]. Outcomes were not so favorable for children with microcystic disease. Disease in the locations in the parotid, laryngopharyngeal, or oral regions was frequently extensive and often demonstrated a microcystic component of malformations [18].

We didn't have any serious bedside effect after OK-432 immunotherapy, but the effect of treatment decreased and the number of sessions and the general dose of OK-432 increased from stage I to stage IV and V. We didn't receive satisfactory results in patients with stage IV due to microcystic forms in all cases, and in children with stage V due to significant distribution.

We used OK-432 to treat LM of other sites, but the series is not enough for statistical analysis. The present study is limited by its nonrandomized design. The present work reviews only a 2-year experience in a single center. However, the follow-up time isn't very long. But since the introduction of OK-432 immunotherapy for the treatment of LMs in our clinic, it has been applied in most cases of children with head and neck LM (82.2%).

In conclusion, our results clearly show that OK-432 immunotherapy is safe, effective, and simple to use, and is especially useful in surgically-challenging areas. The result of treatment depends not only on cystic size but on anatomic location and extent of lesions. Response to treatment was most successful in unilateral, isolated, macrocystic LM of the neck.

OK-432 treatment is limited by recurrent inflammation and massive bleeding in the cyst that make it impossible to differentiate lymphatic and venous malformation. An additional disadvantage of OK-432 therapy as with other sclerotherapy is lack of a definitive histological diagnosis.

References

1. Acevedo JL, Shah RK, Brietzke SE. Nonsurgical therapies for lymphangiomas: a systematic review. Otolaryngol Head Neck Surg 2008; 138(4):418-424.
2. Gilony D, Schwartz M, Shpitzer T, Feinmesser R, Kornreich L, Raveh E. Treatment of lymphatic malformations: a more conservative approach. J Pediatric Surgery 2012; 47(10):1837–1842.
3. Perkins JA, Manning SC, Tempero RM, Cunningham MJ, Edmonds JL Jr, Hoffer FA, et al. Lymphatic malformations: review of current treatment. Otolaryngol Head Neck Surg 2010; 142(6):795-803, 803.e1. doi: 10.1016/j.otohns.2010.02.026
4. Churchill P, Otal D, Pemberton J, Ali A, Flageole H, Walton JM. Sclerotherapy for lymphatic malformations in children: a scoping review. J Pediatr Surg 2011; 46(5):912-22.
5. Ogita S, Tsuto T, Tokiwa K, Takahashi T. Intracystic injection of OK-432: a new sclerosing therapy for cystic hygroma in children. Br J Surg 1987; 74(8):690-1.
6. Smith MC, Zimmerman MB, Burke DK, Bauman NM, Sato Yu, Smith RJ. Efficacy and Safety of OK-432 Immunotherapy of Lymphatic Malformations. Laryngoscope 2009; 119(1):107-15. doi: 10.1002/lary.20041
7. Claesson G, Kuylenstierna R. OK-432 therapy for lymphatic malformation in 32 patients (28 children). Int J Pediatr Otorhinolaryngol 2002; 65(1):1-6.
8. De Serres LM, Sie KCY, Richardson MA. Lymphatic malformations of the head and neck. A proposal for staging. Arch Otolaryngol Head Neck Surg 1995; 121(5):577-582.
9. Mulliken JB, Glowacki J. Hemangiomas and vascular malformations in infants and children: a classification based on endothelial characteristics. Plast Reconstr Surg 1982; 69(3):412-22.
10. Al-Adnani M, Williams S, Rampling D, Ashworth M, Malone M, Sebire NJ. Histopathological reporting of paediatric cutaneous vascular anomalies in relation to proposed multidisciplinary classification system. J Clin Pathol 2006; 59(12):1278–82.
11. Legiehn GM, Heran MK. A Step-by-Step Practical Approach to Imaging Diagnosis and Interventional Radiologic Therapy in Vascular Malformations. Semin Intervent Radiol 2010; 27(2):209–231. doi: 10.1055/s-0030-1253521
12. Rautio R, Keski-Nisula L, Laranne J, Laasonen E. Treatment of lymphangiomas with OK-432 (Picibanil). Cardiovasc Intervent Radiol 2003; 26(1):31-6. doi: 10.1007/s00270-002-1980-3
13. Richter GT, Friedman AB. Hemangiomas and vascular malformations: current theory and management. Int J Pediatr 2012; 2012:645678. doi: 10.1155/2012/645678
14. Giguère CM, Bauman NM, Sato Y, Burke DK, Greinwald JH, Pransky S, et al. Treatment of lymphangiomas with OK-432 (Picibanil) sclerotherapy: a prospective multi-institutional trial. Arch Otolaryngol Head Neck Surg 2012; 128(10):1137-44. doi:10.1001/archotol.128.10.1137
15. Ogita S, Tsuto T, Nakamura K, Deguchi E, Tokiwa K, Iwai N. OK-432 therapy for lymphangioma in children: why and how does it work? J Pediatr Surg 1996; 31(4):477-80.
16. Wiegand S, Eivazi B, Sel S, Renz H, Werner JA Folz BJ. Analysis of Cytokine Levels in Human Lymphangiomas. In Vivo 2008; 22: 253-6.
17. Yoo JC, Ahn Y, Lim YS, Hah JH, Kwon TK, Sung MW, et al. OK-432 sclerotherapy in head and neck lymphangiomas: long-term follow-up result. Otolaryngol Head Neck Surg 2009; 140(1):120-3. doi: 10.1016/j.otohns.2008.10.026
18. Boardman SJ, Cochrane LA, Roebuck D, Elliott MJ, Hartley BE. Multimodality treatment of pediatric lymphatic malformations of the head and neck using surgery and sclerotherapy. Arch Otolaryngol Head Neck Surg 2010; 136(3):270-6. doi: 10.1001/archoto.2010.6