

The Occurrence of Potentially Malignant Disorders in the Oral Cavity: A Survey from Bagru-Khurd of Rural Jaipur, Rajasthan

Acharya Siddharth, PG¹; N. Anup, PhD¹; Binjoo Nagesh, PhD²; Bhargava Puneet³;
Shwkhawat Chandni °; Handa Roopika”.

¹Jaipur Dental College, Jaipur, Rajasthan

²Rajasthan Dental College & Hospital, Jaipur, Rajasthan

³NIMS Dental College & Hospital, Jaipur, Rajasthan

°Government Dental College, Jaipur, Rajasthan

”M. M. College of Dental Sciences and Research, Maullana, Ambala, Haryana, Rajasthan

Abstract

Background: India accounts for about 33% of the world's oral cancer as a result of the prevailing unhealthy oral hygiene and detrimental oral habits, such as the consumption of smoked or smokeless tobacco.

The objective of this study is to determine the occurrence of premalignant lesions and conditions in the oral cavity among the different age groups and gender in the Bagru-Khurd region of rural Jaipur (Rajasthan) and to assess the degree of awareness of the ill-effects of consuming smoked or smokeless tobacco.

Material and Methods: In this study 114 patients presenting premalignant lesions or conditions were included. They had been reported in the OPD records of the Rajasthan Dental College and Hospital.

Results: Predominantly potentially malignant disorders were observed within the age group of 30-60 years, among which smoker's palate lesions were most predominant. Besides, Leukoplakia and Tobacco pouch keratosis were also presented in some. Oral Submucous Fibrosis (OSF) and smoker's melanosis as premalignant conditions were presented in a few.

Conclusion: Although the elderly and most women were aware of the ill-effects of tobacco consumption, several patients were unaware.

Keywords: *potentially malignant disorder; oral submucous fibrosis; leukoplakia smoker's palate; tobacco pouch keratosis.*

Introduction

Oral cancer is the eleventh most common cancer in the world [1]. India accounts for one-third of the world's oral cancer resulting from the practice of unhealthy oral hygiene and detrimental oral habits, including the consumption of smoked or smokeless tobacco. In fact, 13–50% of the student population chew pan masala and gutka on a regular basis (Gupta and Ray, 2003).

Pre-cancer refers to an altered state of tissues, which have a high potential to undergo malignant transformation. In 1978, WHO classified the following clinical presentations of the oral cavity to be precancerous:

- Precancerous lesions: A morphologically altered tissue in which the oral cancer is more likely to occur than its apparent normal counterpart. (Leukoplakia, Smoker's Palate);
- Precancerous conditions: A general state associated with significantly increased risk of cancer (Oral Submucous Fibrosis, Lichen Planus) [2].

The concept of labeling certain lesions on the oral mucosa as potentially malignant is based on the evidence of some longitudinal studies, which differentiate areas of the tissues with certain alterations in clinical appearance. These

*Corresponding author: Dr. Siddharth Acharya.
92/174 Aggarwal Farm, Mansarovar, Jaipur 302020.
Phone: +91-9929305114; E-mail : siddharth.acharya@gmail.com

alterations, particularly the red and white patches, coexist along the margins of oral sub-mucous carcinoma.

Sir James Paget, in 1851, observed the potential of the pipe-smoker's palate or 'leukokeratosis' for cancer, and later in 1870 inferred that oral 'ichthyosis' was a significant indication for lingual carcinoma. In 1877, Schwimmer coined the term 'leukoplakia' for white tongue changes seen prior to lingual cancer development in tertiary syphilis [3]. The classic review by Goodale in 1900, established oral leukoplakia as the precursor to lingual cancer, most often observed in the area, prior to the occurrence of the cancer. Data until the present day suggest that about 2–12% cases of oral precancerous lesions and conditions have a tendency to develop malignancy [4].

Alarming Status of oral cancer in India

From among the over 390,000 oral and oropharyngeal cancers estimated to occur annually globally, 58% occur in South and South-East Asia. India alone accounts for 75,000 – 80,000 new cases of oral cancer diagnosed annually. The incidence rates of cancers of the oral cavity in males and females are the highest in the world in India, most commonly seen in the middle-aged and older individuals. A large percentage of the oral cancers in India progress from leukoplakia [4].

The predisposing factors that have been identified as associated with oral cancer include tobacco, alcohol, betel quid, smoked tobacco, malnutrition, poor oral hygiene and spices (Balaram et al 2002, Rajkumar et al 2003). The most potent carcinogens in tobacco are specific nitrosamine and polycyclic aromatic hydrocarbons (Mehta, 1993). The heat together with the effects of the cigarette smoke can lead to the formation of precancerous lesions as has been detected by (Ogden et al.,1996).

Aims and Objectives

- To determine the occurrence of premalignant lesions and conditions in the oral cavity among the different age groups and gender in the Bagru-Khurd region of rural Jaipur (Rajasthan).
- To understand the awareness of the ill-effects of consuming tobacco among persons who regularly consume tobacco in its varied forms – smoked or smokeless.

Material and Methods

A total of 114 patients were selected who had reported in the OPD records of the Rajasthan Dental College and Hospital, Jaipur, during the study period. Subjects presenting premalignant lesions or conditions of all ages and either gender were selected, irrespective of their awareness of the presence of these lesions and/or conditions. The sample was self-selected as it was drawn from patients who visited the hospital for treatment. Patients habituated to consuming carcinogenic substances but who had not as yet developed a precancerous lesion or condition, as well as those who had developed full-fledged carcinoma when they had reported in the hospital were excluded from the study sample.

Each of the premalignant lesions and conditions were appropriately coded. A questionnaire containing 13 questions

related to each patient's oral hygiene habits, the form and frequency of consumption of the carcinogenic substances, patient experience of any difficulty in consuming food or in mouth opening. The questionnaire was in English and was filled up by the investigator. The clinical examination included the region of the oral cavity affected by the potentially malignant disorder. The same investigator filled up the questionnaire and performed the clinical examination.

Results

Of the 114 cases in total, 106 males and 8 females were examined. The sample presents a huge male-bias in persons visiting the hospital for oral diagnosis and treatment. The cases of potentially malignant disorders predominantly fell within the age group of 30-60 years. 21 (18.4%) of the 114 cases examined suffered from OSMF. Of these 21 cases, 10 (47.6%) cases occurred between the ages of 21-30 years.

Cases with one Pre-malignant lesion: At least one premalignant lesion, either Leukoplakia or Smoker's Palate or Tobacco Pouch Keratosis was noted among the cases examined. Fig. 1 suggests that the 56% (64 cases) of patients examined had Smoker's Palate, while another 2% cases having more than one lesion suffered from Smoker's Palate. The next most commonly noted lesion was the one associated with the habit of betel quid chewing. 18% (20 cases) presented tobacco pouch keratosis. Another 3% had a second lesion as tobacco pouch keratosis. Of those 64 cases who presented with one single premalignant lesion, 31 (48.4%) cases were of Smoker's Palate, occurring within the age group of 41 to 60 years while 15 cases i.e. 23.43% fell in the age range of 31 to 40 years. 11(17.2%) and 7 (10.9%) cases aged occurred between 21 to 30 years and 61 to 80 years, respectively. There were no cases of Smoker's Palate noted in patients younger than 20 years of age and over 80 years of age. This observation was due to the fact that younger age groups have relatively less smoking habits, and among those who do, the time period is limited. Smoker's Palate is not caused by the nicotine per se, but by the heat generated due to smoking.

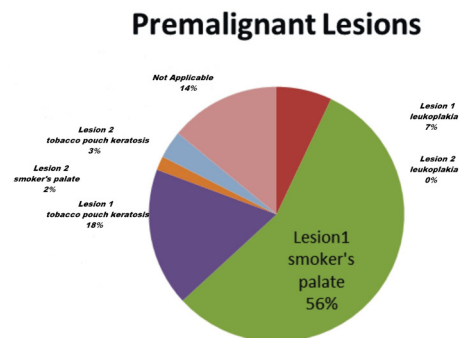


Figure 1.

Fig. 2 shows that almost 79% (90 cases) of the 114 patients examined did not suffer from any oral premalignant conditions. Of the remaining 24 cases, 87.5% (21 cases) presented oral sub-mucous fibrosis. The frequency of chewing tobacco is

an important factor in the patient developing the condition as against the duration for which smokeless tobacco is consumed at a given point of time. Of the 114 cases examined, 3 (2.6%) cases of smoker's melanosis were reported, while none of the cases were observed to have lichen planus.

Premalignant Conditions

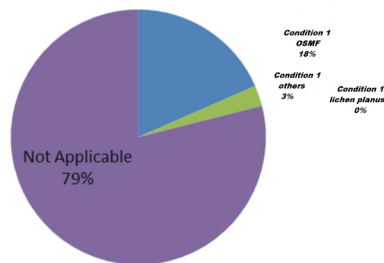


Figure 2.

Fig. 3 reveals a considerable discrepancy in the awareness of the ill-effects of the abuse of carcinogens like smoking and tobacco. A total of 31 cases observed in the age group of 21 to 30 years were found to be aware of the ill-effects of carcinogens, whereas 3 cases were unaware. As against this, 46 patients between the ages of 41 and 60 years were not at all aware, while only 15 cases acknowledged that the abuse of carcinogens was indeed harmful to health. Among the age group of 60 to 80 years, 5 of the 7 cases examined were unaware regarding the ill-effects of the use of carcinogens and only 2 were aware that carcinogen usage should be avoided. Of the total of 8 females who were part of the study, half of the cases had some awareness regarding the ill effects of the carcinogens. 64% (73 of the 114 cases) of the cases examined, were aware of the ill effects of the abuse of carcinogens. Interestingly, these patients also found it difficult to quit their habit of consumption of these substances.

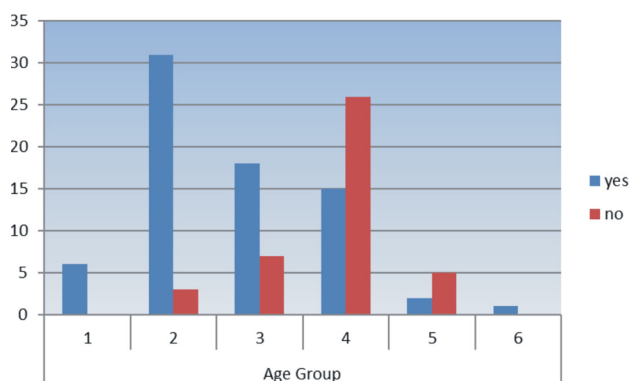


Figure 3.

Discussion

Premalignant lesions and conditions of the oral cavity are extensively present among persons in the 30-60 year age group in Bagru-Khurd, Jaipur district, who also consume

pan and tobacco along with smoked tobacco. Other studies too suggest the higher incidence of patients visiting dental hospitals in this age profile [1,4] as they indulge in tobacco use and gradually develop lesions which bring them to the hospital seeking treatment. The smoking habit is evident more in the middle-aged and elderly patients and most patients in this study fall into this age category [2]. In this region, there are mostly male tobacco smokers, and therefore, the carcinogenic effect is observed in more males than females. The elderly population is more affected because the younger generation are more aware of the ill-effects of tobacco consumption.

The results of this study indicate OSF in 20% cases. Studies have suggested that the OSF mostly occurs among the people in India, as the predisposing factors of OSF are mainly chewing nuts and spices and the frequent chewing of tobacco [1,4]. People in this region (Bagaru Jaipur) also consume significant quantities of spices and are habituated to nut and tobacco chewing. Hence, the results of the present study concur with those of the studies conducted earlier. Also, the frequency of the habit of consuming smokeless or smoked tobacco plays an important role in the development of nicotine palatinus. As nicotine has the potential to become addictive to its users, the frequency of its consumption inevitably increases over time, resulting in patients eventually developing a lesion. Possibly, people smoke despite being aware of the ill effects, as nicotine is highly addictive. Subsequently, the frequency of use meteorically rises, resulting in lesions. Some studies include Smokers' Palate under the umbrella of Leukoplakia [2]. In this paper, we distinguished Leukoplakia into two categories, as they are both caused through exposure to the different forms of tobacco. In this study most cases were of Smoker's Palate, whereas 7% (8 cases) presented with Leukoplakia. If considered under the same umbrella, the results support other studies which also suggest that Leukoplakia is most common [1,5]. None of the patients in the study group presented lichen planus, which has been reported in lesser numbers in earlier studies [1,6]. Tobacco pouch keratosis constituted 18% of the patients in the present study, a condition which is caused by betel nut chewing, by retaining a quid in the mouth for chewing over extended lengths of time [6-8]. Large numbers of patients are not aware of the ill effects of tobacco consumption, as stated in previous studies [1]. A number of factors contribute to this alarming lack of awareness, including the lack of education, the symptoms emerging only after the prolonged use of tobacco which is rather late, or that they simply do not care as people in their society had been smoking for several generations. Efforts to increase the awareness and to educate the masses regarding the ill effects of the use of tobacco and other carcinogenic factors remain the undisputed challenge for oral health professionals. This is especially important in the rural areas where the penetration of oral health experts in India is extremely limited. This is a long-term and time-consuming process, but will reap unprecedented benefits for a better healthier future for India and her masses.

Authorship

This was a complete team-work and the sequence of authorship is as mentioned above.

Competing interests

The authors declare that they have no competing interests.

References

1. Dhama, Harneeta; Ghaffar, Ayesha; Ghafur, Bushra; Javaid, Khadija. A profile of the premalignant and malignant lesions/conditions in Chennai. 2006-01-23. <http://hdl.handle.net/1905/497>
 2. Bouquot JE. Oral premalignancy; critical analysis and review. The Maxillofacial Centre for Diagnostics & Research. [Cited 2011 Nov 3]. Available from: www.maxillofacialcenter.com/precancerSpeight97.html
 3. Nair U, Bartsch H, Nair J. Alert for an epidemic of oral cancer due to use of the betel quid substitutes *gutkha* and *pan masala*: a review of agents and causative mechanisms. *Mutagenesis* 2004 ; 19(4):251-62.
 4. Mendes SF, Ramos GO, Rivero ERC, Modolo F, Grando LJ, Meurer MI. Techniques for Precancerous Lesion Diagnosis. *Journal of Oncology* 2011; 2011: Article ID 326094.
 5. To study prevalence of precancerous lesions of the oral cavity and their association with areca nut and non-tobacco pan masala conforming areca nut in North Eastern states. WHO. [Cited 2011 Nov 5]. Available from: ftp://203.90.70.117/searoftp/WROIND/whoindia/linkfiles/Health_Environment_Health_areca_nut.pdf
 6. Neville BW, Day T A. Oral cancer and precancerous lesions. *CA Cancer J Clin.* 2002; 52(4):195-215.
 7. Warnakulasuriya S, Johnson NW, van der Waal I. Nomenclature and classification of potentially malignant disorders of the oral mucosa. *J Oral Pathol Med.* 2007; 36(10):575-80.
 8. George A, Sreenivasan BS, Sunil S, Varghese SS, Thomas J, Gopakumar D, Mani V. Potentially malignant disorders of oral cavity. *J Oral Maxillofac Pathol* 2011 ; 2(1):95-100.
-