International Journal of Biomedicine 9(4) (2019) 370-372
http://dx.doi.org/10.21103/Article9(4)_ShC1

SHORT COMMUNICATION

INTERNATIONAL JOURNAL OF BIOMEDICINE

A Method for Performing a Gastrostomy Using a Polypropylene Mesh

Sergey N. Shurygin, PhD, ScD[1]; Alexander V. Kutenev, PhD[2]; Leonid V. Safonov, PhD[1*]; Inna V. Pastukhova, PhD[3]; Irina N. Shurygina[2]; Alexey G. Vaganov[4]; Archil S. Tsulaya[5]

[1]*Federal Scientific Center for Physical Culture & Sports, Moscow, Russia*
[2]*RUDN University, Moscow, Russia*
[3]*First Moscow State Medical University (Sechenov University), Moscow, Russia*
[4]*State Budgetary Institution of Healthcare of the City of Moscow «City Clinical Hospital No.29», Moscow, Russia*
[5]*Budgetary Institution of Health «Clinical Hospital V.M. Buyanova», Moscow, Russia*

Abstract

Gastrostomy is one of the main palliative surgical methods for restoring enteral nutrition. The aim of the study was to develop a new method of gastrostomy that reduces the frequency of complications. The prototype for the described method is Depage-Janeway gastrostomy with use of the GIA stapler. The proposed method is characterized by the use of polypropylene mesh. This provides a tight attachment of the wall of the stomach to the anterior abdominal wall, which reduces the risk of complications. (**International Journal of Biomedicine. 2019;9(4):370-372.**)

Key Words: gastrostomy • palliative surgical methods • polypropylene mesh

Method Description

Gastrostomy is one of the most common palliative operations, the main indication for which is the need to restore enteral nutrition [(1)] in patients with severe neurological diseases associated with impaired swallowing, as well as in patients with a tumor obstruction of the upper digestive tract. However, indications for gastrostomy are constantly expanding and, in addition to solving palliative tasks, it is often used in a complex of rehabilitation [(2)] and therapeutic measures.[(3)] To date, about 100 different modifications of gastrostomy have been published in the literature. According to the method of application, they can be divided into 3 categories: open "traditional" methods (Witzel, Stamm – Kader, Toprover gastrostomy), laparoscopic gastrostomy, and percutaneous gastrostomy under endoscopic or radiological control. The traditional open methods for applying gastrostomy include Witzel gastrostomy,[(4)] which is still one of the most common operations performed in general surgical hospitals.[(5)]

Accordingly, with the expansion of indications for gastrostomy, this operation is still relevant to the improvement of existing gastrostomy techniques and the development of new ones;[(6)] it reduces the risk of gastrostomy insolvency, gastrostomy tube migration, and wound complications due to leakage of the structure, and it eliminates the need for the use of additional devices that fix the gastrostomy tube.

The purpose of the work was the development of a new method of gastrostomy to improve the treatment results in patients who have indications for applying gastrostomy.

Closest to the proposed method is Depage-Janeway gastrostomy using the GIA stapler.[(7)] This method was taken as a prototype method. The method of gastrostomy using a polypropylene mesh (Patent RU No. 2691924; priority of 06.18.2019; Bulletin No. 17) is implemented as follows. An upper median laparotomy is performed. The anterior wall of the stomach (Fig.1) is pulled up with two Babcock clamps to form a gastric tube 8-10 cm long. In addition, the diameter of the tube is calculated so that it allows insertion and removal of a Foley (18-22 F) catheter for feeding the patient. A GIA type stapler is placed perpendicular to the greater curvature of the stomach. The apparatus suture should end 2.5 cm from the greater curvature of the stomach. The device leaves 4 rows of sutures, 2 on each side, in the form of a double variable line of brackets. At the same time, the knife of the GIA apparatus cuts the stomach between both double rows of sutures, forming a closed gastric tube in the form of a diverticulum with a

***Corresponding author**: Leonid V. Safonov, PhD. Federal Scientific Center for Physical Culture & Sports; Moscow, Russia. E-mail: lsaf@mail.ru*

base at the greater curvature of the stomach. The apparatus suture is placed as the knotted cotton or silk seams. From a polypropylene mesh, 2 polypropylene mesh implants are modeled (Fig.1). The first of them is cut out in the form of an oval plate with a diameter of 6-7 cm, with a central hole (7 mm in diameter) through which the gastric tube is drawn. The second implant is cut out in a rectangular shape along the length of the gastric tube. The stomach tube is passed through the first implant, which is fixed to the gastric wall along the perimeter by separate sutures with 3/0 polypropylene thread. The second implant, in the form of a clutch, wraps the gastric tube and is fixed on the gastric tube with individual polypropylene sutures. Two implants are sutured together by separate sutures with 2/0 polypropylene thread. To the left of the midline incision, a hole of 1.5-2 cm is made in the projection of the left rectus abdominis muscle, where a Foley catheter (18-22F) is inserted into the abdominal cavity. The gastric tube is crossed along the diameter of the catheter, the catheter is inserted into the lumen of the stomach, and the catheter balloon is inflated through a special cannula. The gastric tube is fixed with separate sutures of polypropylene 2/0 thread to the parietal peritoneum and the muscular aponeurotic layer.

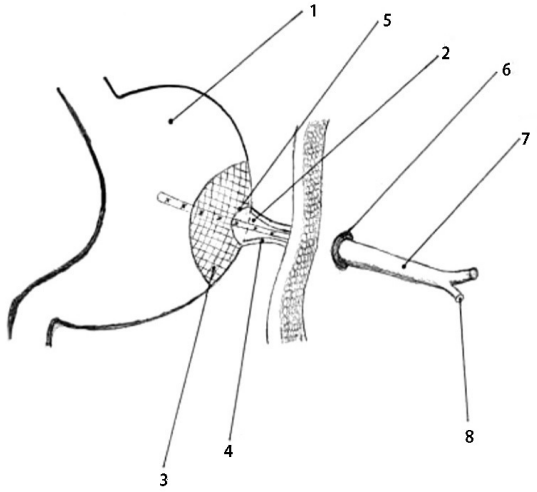

Fig. 1. *The first stages of gastrostomy using a polypropylene mesh. General view of the stomach with a formed gastric stalk with two mesh implants.*

1. The anterior wall of the stomach; 2. Gastric tube; 3. The first polypropylene mesh implant (oval shape); 4. The second polypropylene mesh implant (rectangular shape); 5. A surgical hole of 1.5-2 cm in the greater curvature of the stomach; 6. Aperture in the anterior abdominal wall through which the gastric tube is drawn; 7. Foley catheter; 8. Cannula for inflating a Foley catheter

In three places in the projection of the first implant, the anterior abdominal wall is stitched (Fig.2), as well as the wall of the stomach, with a mesh fixed by a serous-muscular suture with polypropylene 1/0 thread. The wall of the stomach is firmly pressed to the anterior abdominal wall. On the skin, 3 knots are tied. Hemostasis is performed. Laparotomic wound is sutured in layers. Further, during the course of the postoperative period with daily wound treatment, changing dressings after 3 weeks, the stomach-fixing sutures are gradually removed as the implants germinate with connective tissue, which provides an increasingly tight attachment of the stomach wall to the anterior abdominal wall.

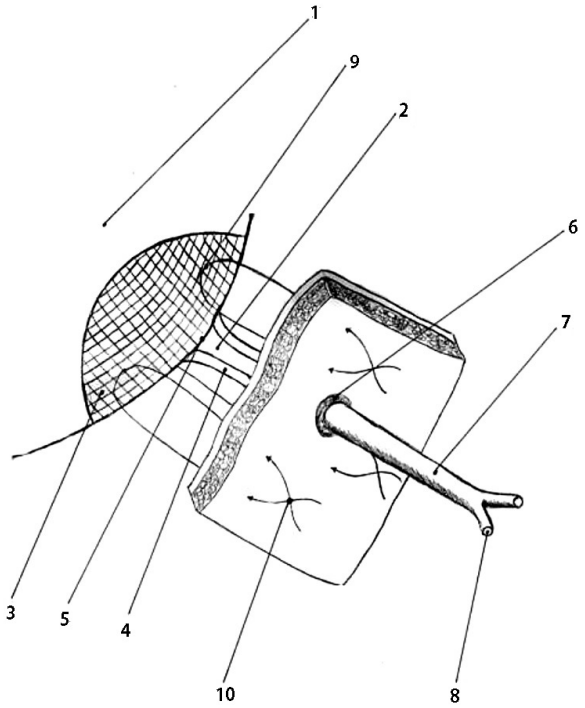

Fig. 2. *The final stages of the gastrostomy using a polypropylene mesh. In three places in the projection of the first implant, the anterior abdominal wall is stitched, as well as the wall of the stomach, with a mesh fixed by a serous-muscular suture with polypropylene thread. The wall of the stomach is firmly pressed to the anterior abdominal wall. On the skin, 3 knots are tied.*

1. The anterior wall of the stomach; 2. Gastric tube; 3. The first polypropylene mesh implant (oval shape); 4. The second polypropylene mesh implant (rectangular shape); 5. A surgical hole of 1.5-2 cm in the greater curvature of the stomach; 6. Aperture in the anterior abdominal wall through which the gastric tube is drawn; 7. Foley catheter; 8. Cannula for inflating a Foley catheter; 9. A mesh fixed by a serous-muscular suture with polypropylene 1/0 thread; 10. 3 knots on the skin

The proposed method for performing gastrostomy using a polypropylene mesh is industrially applicable, because for its implementation in modern medical institutions with surgical hospitals, all the necessary materials and tools are available.

Discussion and Conclusions

When installing mesh endoprostheses, which is accompanied by violating the integrity of the anterior abdominal wall, there are a number of issues related to the development of postoperative complications: the formation of seroma or hematoma, vascular erosion, migration of the implant into

the abdominal cavity with the formation of pressure sores and intestinal fistulas,[8] a decrease in the physiological mobility of the abdominal wall, the formation of an adhesive intestinal obstruction in connection with the adhesion of the serous membrane of the small intestine.[9] The specific advantages of the proposed gastrostomy method are: 1) achieving tight attachment of the stomach wall to the anterior abdominal wall, which is absolutely necessary for a certain category of patients with a reduced level of reparative processes; 2) reducing the risk of postoperative ventral hernias; 3) eliminating the need for additional devices to fix the gastrostomy tube; 4) easing the maintenance of the gastrostomy tube, in particular, the procedure for replacing gastrostomy tubes—all of which taken together lead to a decrease in the number of complications, including in the long term.

At the present stage of development of palliative medicine, requirements are imposed to bear in mind the quality of life of the patient in the postoperative period.[9] Moreover, the quality of life is considered as a criterion for the effectiveness of rehabilitation measures.[10] The formation of a controlled, localized adhesive process between the wall of the stomach and the anterior abdominal wall avoids a decrease in the quality of life associated with the sensation of an implant in the area of the operation and intense pain in the early and late postoperative periods; it also facilitates the care of the gastrostomy and increases the mobility of patients in need of a long-lasting gastrostomy.

The risk of gastrostomy insolvency, migration of the gastrostomy tube, is reduced when using the developed method of gastrostomy because the implants perform a strengthening function in relation to the anterior abdominal wall. The need to use additional devices that fix the gastrostomy tube is eliminated due to the tight attachment of the stomach to the anterior abdominal wall. The number of wound complications is also reduced because this gastrostomy is closed and gastric contents do not get on the skin.

Competing interests

The authors declare that they have no competing interests.

References

1. Fávaro GM, Filho TF, Coca DS, Cunha MA, Sato Uemura R, Furuya Júnior CK, Aparício D, Artifon ELA. Endoscopic gastrostomy: critical analysis in a regional referral hospital. Rev Gastroenterol Peru. 2017;37(1):33-38.
2. Qureshi AZ, Jenkins RM, Thornhill TH. Percutaneous endoscopic gastrostomy versus nasogastric tube feeding during neurorehabilitation. Neurosciences (Riyadh). 2016;21(1):69-71.
3. Thompson CC, Abu Dayyeh BK, Kushner R, Sullivan S, Schorr AB, Amaro A, Apovian CM, Fullum T, Zarrinpar A, Jensen MD, Stein AC, Edmundowicz S, Kahaleh M, Ryou M, Bohning JM, Ginsberg G, Huang C, Tran DD, Glaser JP, Martin JA, Jaffe DL, Farraye FA, Ho SB, Kumar N, Harakal D, Young M, Thomas CE, Shukla AP, Ryan MB, Haas M, Goldsmith H, McCrea J, Aronne LJ. Percutaneous Gastrostomy Device for the Treatment of Class II and Class III Obesity: Results of a Randomized Controlled Trial. Am J Gastroenterol. 2017;112(3):447-457. doi: 10.1038/ajg.2016.500.
4. Witzel O. Zur technic der magenstelanlegung. Zentralbl Chir.1891:18:601.
5. Barykin AS, Kozin SM, Savvin VYu, Dobrodeev SA, Vakhonin AYu. [Percutaneous endoscopic gastrostomy]. Endoscopic surgery. 2007;(1):115-6.[Article in Russian].
6. Lee SP, Lee KN, Lee OY, Lee HL, Jun DW, Yoon BC, Choi HS, Kim SH. Risk factors for complications of percutaneous endoscopic gastrostomy. Dig Dis Sci. 2014;59(1):117-25.
7. WHO. Planning and implementing palliative care services: a guide for program managers. Copenhagen: World Health Organization Regional Office for Europe; 2018.
8. Bazaev AV, Goshadze KA, Malov AA,Yanyshev AA. [Migration of Polypropylene Mesh Into the Abdominal Cavity after Hernia Repair of Recurrent Postoperative Ventral Hernia (Clinical Case)]. Journal of New Medical Technologies. 2016;(1):59-61. [Article in Russian].
9. Kasymov AA, Musaev US. [Results of surgical treatment of patients with strangulated postoperative ventral hernias using with polypropylene mesh]. Privolzhsky Nauchnyi Vestnik. 2016;11(63):54-57. [Article in Russian].
10. Zvyagina NM, Kudrenko SS, Antonov OV. [Life quality as an efficiency criterion on assessment of medical and rehabilitational programs]. Journal of Siberian Medical Sciences. 2015;(6):30. [Article in Russian].