International Journal of Biomedicine 12(1) (2022) 124-133
http://dx.doi.org/10.21103/Article12(1)_OA13

ORIGINAL ARTICLE

Experimental Medicine

INTERNATIONAL JOURNAL OF BIOMEDICINE

Effectiveness of Experimental Colitis Therapy with Original Vitamin D_3 Rectal Suppositories

M. V. Osikov[1,2]; M. S. Boyko[1*]; A. A. Fedosov[3,4]; M. A. Ilyinykh[1]

[1]*South Ural State Medical University, Chelyabinsk, Russia*
[2]*Chelyabinsk Regional Clinical Hospital, Chelyabinsk, Russia*
[3]*Russian National Research Medical University named after N.I. Pirogov, Moscow, Russia*
[4]*Peoples' Friendship University of Russia (RUDN University), Moscow, Russia*

Abstract

Background: Pathogenesis of inflammatory bowel disease (IBD) is insufficiently explored, while most of the therapeutic agents used for IBD cases have undesirable side effects, which restrict their administration.The aim of this research was to study the influence of vitamin D3 formulated into original rectal suppositories on the parameters of clinical score, morphology, and oxidative lipid and protein destruction in the colonic lesion in the cases of experimental colitis (EC).

Methods and Results: The experiment was performed on 98 Wistar male rats weighing 210-230 g. EC condition was induced by two-phase administration (dermal application and per rectum) of 3% alcohol solution of oxazolone. Originator polyethylene glycol-based suppositories, which contained 1500 ME of vitamin D3, were administered per rectum every 12 hours. Clinical score was defined according to the Disease Activity Index (DAI) scale. Morphometry was run using the software program "ImageScope M" (Russia). Damage of the colonic tissue was estimated on Tissue Damage Index (TDI).

The following parameters were determined in the colonic lesion: neutrophil count (NC), lymphocyte count (LC), eosinophil count (EC), histiocyte count (HC), plasma cell count (PC), fibroblast count (FC), the diameter of the ulcerous defect, TDI, MPO expression, and TNF-α expression. The following parameters were determined in the damaged tissue homogenate: lipid peroxidation product count (LPP) and protein oxidative modification (POM) count.

In cases of oxazolone-induced EC, on Days 2, 4, and 6, we registered clinical and laboratory signs, an ulcerous defect in the damaged area of the colon, all of which are typical for IBD conditions. There was an increase in DAI (peak on Day 6) and TDI (peak on Day 2). We also found an increase in NC (peak on Day 2), LC (peak on Day 6), EC (peak on Day 2), PC (peak on Day 2), HC (peak on Day 2), and FC (peak on Day 2). There was an increase in MPO expression (peak on Day 2) and TNF-α expression (peak on Days 2 and 4). We observed increases in the primary, secondary, and end LPP counts and the early-phase and late-phase POM counts in spontaneous and induced modes.

An administration of 1500 ME vitamin D3 rectal suppositories every 12 hours for 6 days decreased the severity of clinical manifestations and DAI. It reduced the area of the ulcerous defect and decreased the TDI on Days 4 and 6 of the experiment. On the background of using vitamin D3 rectal suppositories, we found a decrease in NC, EC, LC, and PC in the damaged area and an increase in HC and FC on Days 2, 4, and 6 from the start of the experiment. Administration of D3 rectal suppositories decreased MPO expression and TNF-α expression on Days 4 and 6 of EC. In the damaged area of the colon, we observed a decrease in the counts of the primary, secondary, and end LPP on Days 4 and 6 of the experiment. We also documented a decrease in the POM count in spontaneous mode on Day 2 and on Day 6 in induced mode.

Conclusion: Vitamin D3 as a constituent of originator rectal suppositories in total dose 18,000 ME in the pre-clinical phase of EC decreases the intensity of EC clinical manifestations. It reduces the count of the cells that take part in tissue destruction in the colonic wall, of TNF-α and MPO expression levels, and LPP- and POM product count. It increases the count of the cells, which promotes tissue reparation. The obtained results are essential for carrying out further research aimed at elaboration of the mechanism of the D3 effect in cases of IBD and at its possible clinical use.(**International Journal of Biomedicine. 2022;12(1):124-133.**)

Key Words: experimental colitis • rectal suppositories • vitamin D_3 • oxidative stress

For citation: Osikov MV, Boyko MS, Fedosov AA, Ilyinykh MA. Effectiveness of Experimental Colitis Therapy with Original Vitamin D3 Rectal Suppositories. International Journal of Biomedicine. 2022;12(1):124-133. doi:10.21103/Article12(1)_OA13

Abbreviations

DAI, disease activity index; **EC**, experimental colitis; **EC**, eosinophil count; **FC**, fibroblast count; **HC**, histiocyte count; **IBD**, inflammatory bowel disease; **LPP**, lipid peroxidation product; **LC**, lymphocyte count; **NC**, neutrophil count; **OS**, oxidative stress; **POM**, protein oxidative modification; **PC**, plasma cell count; **ROS**, reactive oxygen species; **TDI**, tissue damage index.

Introduction

Inflammatory bowel diseases (IBD) include diseases with multiple etiology, which are characterized by chronic inflammatory-destructive progressive damage of the gastrointestinal tract by the systemic immunological factors under the conditions of immune response dysregulation. The incidence of autoimmune gastrointestinal disorders has only been increasing for the last ten years. The annual rate of increase in the number of IBD cases is 5-20 cases per 100,000 people, and the number is continuing to grow.[1,2,3] Pathogenesis of IBD is insufficiently explored, while most of the therapeutic agents used for IBD cases have undesirable side effects, which restrict their administration. In IBD pathogenesis, the following factors damage the colonic wall: Th2-dependent reactions involving IgM and IgG, as well as Th-1 dependent reactions with increased production of IL-8, TNF-α, and other cytokines; the activation of chemotaxis; absorption and killing activity of neutrophils, monocytes/macrophages; and the production of ROS and nitrogen.

Hyperproduction of ROS in combination with a decreased activity of the antioxidant system leads to the progression of oxidative stress (OS) and accumulation of irreversible products of protein oxidative modification (POM) – i.e. carbonyl derivatives and lipid peroxidation products (LPP).[4] The mentioned changes on the morphological level lead to damaging of distal colonic regions, to the destruction of intestinal glands, to goblet cell hyperplasia, mucous ulceration and fibrosis, which clinically manifest as tenesmus, changes of stool consistency, an admixture of blood in fecal matter, body mass deficiency and other symptoms, including intestinal and extraintestinal complications.[5-7] The essential IBD therapy includes topical and systemic inflammatory inhibitors (5-aminosalicylate, corticosteroids), immunosuppressive agents(azathioprine, 6-mercaptopurine, etc.), and biologic therapy medications(infliximab, adalimumab, golimumab, etc), all of which have a wide variety of undesirable side effects on the gastrointestinal tract, the hemic system, and the reproductive system. These treatments do not guarantee achieving long-term remission. About 30% of IBD patients develop resistance to therapy and medication intolerance in cases of long-term use. Therefore, elaboration of new IBD treatment approaches is urgent.[8,9] In this aspect, vitamin D3 is of certain interest because of its pleiotropic qualities (antioxidative, anti-inflammatory, immunomodulatory, and other).[10-12] Administration of vitamin D3 in cases of multiple sclerosis and psoriasis limits the severity of inflammatory process and clinical signs due to increased IL-10 production and Treg count in blood, and a shift in Th1/Th2 balance to the side of Th2-dependent immune response.[13,14] In the presence of rheumatoid arthritis, vitamin D3 represses the activity of Th17 and the production of IL-17.[15] The stated facts serve as a ground for clinical usage of vitamin D3 in IBD cases.[16] As of now, in the CIS countries, there are no dosage forms for using vitamin D3 locally *per rectum* aimed at the impact on the area of inflammation and the damaged colonic section in cases of IBD. We have developed original rectal D3 suppositories based on a 10% D3 aqueous solution.[17] Formerly we proved that vitamin D3 as a constituent of original rectal suppositories in cases of experimental colitis (EC) has a systemic immunotropic effect, decreases blood neutrophil count, restores absorption and NBT-reducing activity of neutrophils, decreases LC, including CD3+ and CD45RA+, and decreases the concentration of IgM, IgG, IL-6, and IL-8.[18] We assume that the systemic immunotropic effect of vitamin D3 formulated into original rectal suppositories in EC cases is associated with its local protective action in the colonic lesion. The aim of this research was to study the influence of vitamin D3 formulated into original rectal suppositories on the parameters of clinical score, morphology, and oxidative lipid and protein destruction in the colonic lesion in EC cases.

Materials and Methods

The experiment was performed on Wistar male rats weighing 210-230g. All stages of the experiment were carried out in accordance with the requirements of Directive 2010/63/EU of the European Parliament and of the Council of 22 September 2010 on the protection of animals used for scientific purposes.[19]

Ninety-eight rats were randomly divided into three experimental groups: Group 1 included 14 intact animals (control group); Group 2 included 42 animals with EC; Group 3 included 42 animals with EC treated by vitamin D3 rectal suppositories every 12 hours for 6 days until withdrawn from the experiment.

EC condition was induced by two-phase administration of oxazolone ("Sigma-aldrich", USA). In the first phase, sensibilization was performed by a dermal application between the shoulders of 150 µl of 3% alcohol solution of oxazolone. In the second phase, 150 µl of 3% alcohol solution of oxazolone was inserted to the depth of 7-8 cm per rectum (Fig.1).[20] For anesthetic purposes, "Zoletil-100" ("Virbac Sante Animal", France) was administered in a dose of 20 mg/kg. EC diagnosis was verified by estimating the clinical pattern and morphology of the damaged area of the colon.

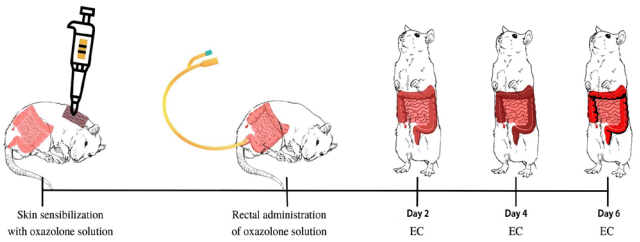

Fig. 1. *EC modeling.*

Vitamin D3 suppositories were based on a 10% aqueous solution of vitamin D3, with a compound of polyethylene glycols with different molecular weights, emulsifier T-2, cremophor RH-40 and kolliphor as excipients. The size and the shape of suppositories answered the specifics of the distal section of rats' colon. The final mass of each suppository was 300 mg; the content of vitamin D3 in each suppository was 1500 ME (Fig,2).[17,21]

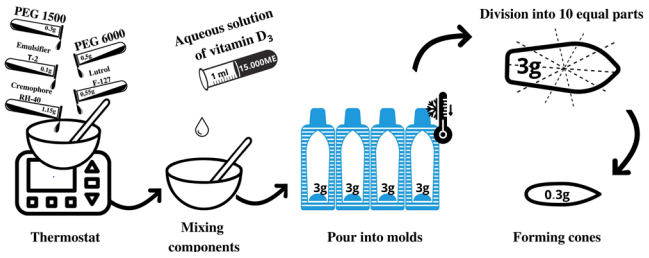

Fig. 2. *Manufacturing technology of vitamin D_3 rectal suppositories.*

The study was run on Days 2, 4 and 6 after EC induction. To estimate clinical score, we used the Disease Activity Index (DAI) scale, which was adapted for rats. It included the following parameters: body mass, stool consistency, and blood admixtures in the excrement.[22] The parameters were calculated daily on a 5-point scale from 0 to 4, with maximum possible DAI – 12.

Segmented intestine distal fragments were fixed in 10% neutral formalin solution; serial sections were stained with H&E. In ten randomly selected fields of vision on a micrograph "Leica DMRXA" (Germany) (×400 magnification), we quantified NC, LC, EC, HC, PC, FC per 1mm^2. At ×100 magnification, we quantified the diameter of the ulcerous defect. Morphometry was run using the software program "ImageScope M" (Russia)

Damage of the colonic tissue was estimated on scale from 0 to 6 with the definition of the relative area of lesion, colonic wall thickness, angiogenesis, goblet cell loss, severity of leucocyte infiltration and Tissue Damage Index (TDI).[23]

Myeloperoxidase (MPO) expression and TNF-α expression in the colon mucosa were estimated by an immunohistochemical test with an antibody kit that was specified for rats ("Cloud. Clon. Corp.", China), and super-adhesive slides with a positively charged surface (Super Frost Plus). The reactions were run in immunohistostainer "Bench Mark XT" (Ventana, USA) with complete adherence to the research protocol. Imaging was carried out in the "Ultra VIEW Universal DAB" system (Ventana, USA) with second-antibody and chromogen complex.

For preparing the 10% colon mucosa homogenate, a proximal part of the segmented intestine was taken from the peritoneal cavity and put into cooled 0.1M phosphate-buffered saline (pH=7.4). After that, approximately 100mg of tissue were homogenized in a glass mechanical homogenizer in a ratio of 1:10 for 3 minutes at a temperature less than 4°C with subsequent generation of 1ml of homogenate.

The LPP level in colon mucosa homogenate was determined by the extraction-and-spectrophotometric method in spectrophotometer "SF-56" ("LOMO-Specter", Russia) according to I.A. Volchegorsky et al.[24,25] The optical density of heptane and isopropanol extracts was measured at 220 nm (isolated double bonds count), 232 nm (diene conjugate count – DC), 278 nm (ketodiene and conjugated triene count – KD and CT), and 400 nm (Schiff's base – SB). Relative LPP count was evaluated in units of oxidation index (u.o.i.): E_{232}/E_{220} (DC), E_{278}/E_{220} (KD and CT), and E_{400}/E_{220} (SB).

POM count in colon mucosa homogenate was defined according to reaction of carbonyl protein compounds with 2,4–dinitrophenylhydrazine in spontaneous and metal-enhanced modes by Fenton's reaction with further spectrometric monitoring of aldehyde-dinitrophenylhydrazine (ADNPH) (early-stage markers of OS) and ketone-dinitrophenylhydrazine (KDNPH) (late-stage markers of OS).[26,27] The results were expressed in optical density units per mg of protein (au/mg).

Statistical analysis was performed using statistical software package SPSS version 23.0 (SPSS Inc, Armonk, NY: IBM Corp). For descriptive analysis, results are presented as median (Me), first quartile (Q1) and third quartile (Q3). A non-parametric Kruskal-Wallis test was used for comparisons of median values among three groups ($P<0.05$), followed by post-hoc testing using un-paired Mann-Whitney U tests. Spearman's rank correlation coefficient (R) was calculated to measure the strength and direction of the relationship between two variables. A probability value of $P<0.01$ was considered statistically significant.

Results and Discussion

Group 2

In cases of EC, on Day 2 of observation, there were the following symptoms: body mass deficiency, frequent defecation, loose stool consistency, and admixture of blood, which could be defined both by the benzidine test and visually.

Table 1.

DAI in the study groups (Me (Q_1; Q_3))

	Group 1 (n=7)	Group 2 Day 2 (n=7)	Group 2 Day 4 (n=7)	Group 2 Day 6 (n=7)	Group 3 Day 2 (n=7)	Group 3 Day 4 (n=7)	Group 3 Day 6 (n=7)
DAI, c.u.	0	7.00 (3.00;7.00)*	8.00 (6.00;10.00)*	11.00 (11.00;11.00)*	5.00 (5.00;5.00)*	4.00 (4.00;5.00)*#	4.00 (4.00;4.00)*#

* - $P<0.01$ with Group 1; # - with Group 2.

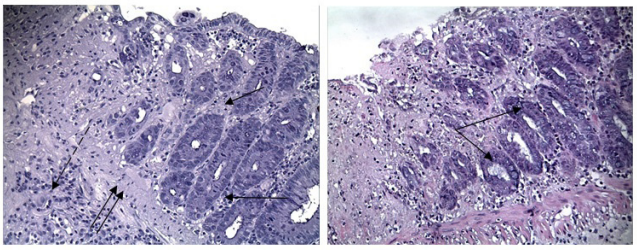

A B

Fig. 3. *Morphological changes in the damaged area of the colon on Day 2 of EC. H&E staining; ×200 magnification. A – Group 2: neutrophil and lymphocyte infiltration of interstitial tissue (arrow), thickening of deep mucosa (double arrow), infiltration of sub-mucous membrane (dotted arrow). B – Group 3: reduced crypts.*

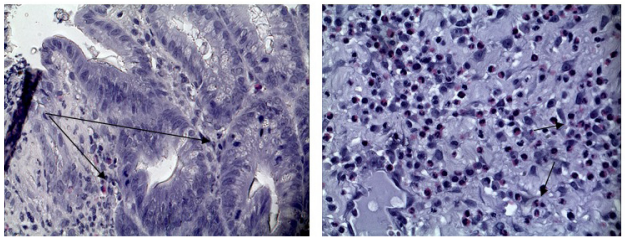

A B

Fig. 4. *Morphological changes in the damaged area of the colon on Day 4 of EC. H&E staining; ×400 magnification. A – Group 2: neutrophil and lymphocyte stromal infiltration with multitude of eosinophil cells. B – Group 3: proliferating fibroblasts.*

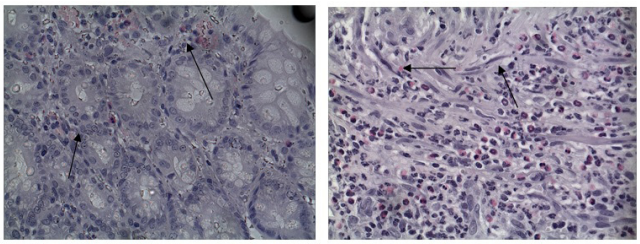

A B

Fig. 5. *Morphological changes in the damaged area of the colon on Day 6 of EC. H&E staining; ×400 magnification. A – Group 2: neutrophil infiltration of connective tissue interlayers. B – Group 3: fibroblast proliferation and fibrillogenesis.*

On Days 4 and 6, the clinical manifestations became more severe. DAI index was scaling up massively on Day 2, on Day 4, and on Day 6 of the experiment. DAI value on Day 6 was higher (P<0.01) than its value on Days 4 and 2 (Table 1).

On Day 2, after EC induction, histological examination of the colonic wall in the place of the lesion showed ulcers with bases situated in deep mucosa (lamina propria) and the surface layers of the submucous membrane. In the same place, we registered cellular infiltration accompanied by interstitial tissue edema, venous and capillary plethora, and crypt epithelium in a state of albuminous degeneration (Fig.3). On Day 4, ulcerative defects, swelling of the interstitial tissue, plethora with leukostasis and leukodiapedesis, plasma impregnation and swelling of the vascular walls, and stromal infiltration persisted (Fig.4). In the depths of ulcerative defects, we observed the proliferation of preserved cambial cells of the intestinal glands. On Day 6, we noticed ulcerous defects with cell debris, edema and maceration of interstitial tissue and vascular plethora (Fig.5). Between the areas of infiltration, there was a distinct proliferation of juvenile fusiform fibroblasts and the initial phase of neoangiogenesis. The edges of the ulcerous defects had distinct signs of epithelialization.

Morphometric evaluation of the cellular composition of the infiltrate in colonic lesions demonstrated a significant increase in NC, LC, PC, FC, in the area of the ulcerous defect, and in the TDI on Days 2, 4, and 6 after EC induction (Table 2). EC progression shows that NC on Day 4 was less (P<0.01) than on Day 2, and on Day 6 less (P<0.01) than on Day 2. LC on Day 6 was higher (P<0.01) than on Day 2 and Day 4. EC, HC, and PC were higher (P<0.01) on Days 4 and 6 than on Day 2. FC on Day 4 was higher (P<0.01) than on Day 2, while FC on Day 6 was higher (P<0.01) than on Days 2 and 4 of the experiment. The area of the ulcerous defect on Days 4 and 6 was bigger (P<0.01) than on Day 2. The peak extent of NC in the lesion was recorded on Day 2, for EC, HC, PC, and FC – on Days 2 and 4, LY – on Day 6 after ES onset.

Expression of MPO and TNF-α increased massively on Days 2, 4, and 6 of EC (Table 3). MPO expression on Day 6 was lower (P<0.01) than on Day 2; TNF-α expression on Day 6 was lower (P<0.01) than on Days 2 and 4.

While estimating LPP count in colonic mucosa lesion homogenate on Day 2, we observed a significant increase in primary, secondary and end LPP count in the heptane phase of the lipid extract. The same applies to the secondary and end LPP count in the isopropanol phase of the lipid extract (Table 4). On Days 4 and 6 of EC, we recorded a significant increase in the primary, secondary and end LPP count in both heptane and isopropanol phases of the lipid extract of colonic mucosa lesion homogenate. With EC progression, in the heptane phase of the lipid extract, the primary LPP count was less (P<0.01) on Day 6 than on Days 4 and 2; the secondary LPP count on Day 4 was higher (P<0.01) than on Days 2 and 6. In the isopropanol phase, the primary LPP count was higher (P<0.01) on Day 4 than on Days 2 and 6; the secondary LPP count was less (P<0.01) on Day 4 than on Day 2, and the secondary LPP count on Day 6 was less (P<0.01) than on Days 4 and 2. In the isopropanol phase, the end LPP count on Day 4 was higher (P<0.01) than on Days 2 and 6.

POM count in the spontaneous mode showed an increase in the total count of protein carbonyl derivatives ADNPH and KDNPH in colonic mucosa lesion homogenate on Days 2, 4, and 6 of EC (Table 5). The total POM count on Day 4 was less (P<0.01) than on Days 2 and 6. The count of ADNPH was less (P<0.01) on Day 4 than on Days 2 and 6. The count of KDNPH was less (P<0.01) on Days 4 and 6 than on Day 2. In the metal-induced mode, we observed the increased total POM count on Days 4 and 6, while the counts

of ADNPH and KDNPH massively increased on Days 2, 4, and 6. With EC progression, total POM count and ADNPH count was higher (P<0.01) on Day 6 than on Days 4 and 2. KDNPH count was higher (P<0.01) on Day 4 than on Day 2, and on Day 6 than on Day 2 (P<0.01) of EC.

Group 3

Under the local application of vitamin D3 in cases of EC, we observed improvement of the rats' clinical condition. There was no decrease in weight; the fecal matter was firmer, an admixture of blood was defined only by a benzidine test.

Table 2.

Morphometric parameters in the damaged area of the colon in the study groups (Me (Q_1; Q_3))

Parameters	Group 1 (n=7)	Group 2 Day 2 (n=7)	Group 2 Day 4 (n=7)	Group 2 Day 6 (n=7)	Group 3 Day 2 (n=7)	Group 3 Day 4 (n=7)	Group 3 Day 6 (n=7)
NC, u/mm^2	204.56 (189.71;223.57)	2651.41 (2558.85;2813.85) *	1518.48 (1121.49;2100.00) *	1333.33 (1213.34;1608.04 *	873.78 (666.67;925.92) *#	550.45 (370.37;1006.03) *#	654.21 (582.53; 804.83) *#
LY, u/mm^2	338.99 (305.14;368.35)	1104.48 (947.67;1333.34) *	1004.55 (880.09;1238.11) *	1667.02 (1302.62;2038.84) *	680.07 (511.78;849.32) *#	710.67 (495.06;733.95) *#	642.19 (582.61;891.11) *#
EC, u/mm^2	146.91 (120.83;176.18)	852.34 (839.46;857.45) *	2671.29 (2352.95;3553.31) *	2380.11 (2110.11;2613.05) *	467.29 (304.57;611.13) *#	852.89 (635.86;1094.25) *#	805.12 (685.42;867.49) *#
HC, u/mm^2	13.47 (13.42;13.65)	571.94 (198.02;750.26) *	1197.11 (1049.31;1614.91) *	1006.03 (970.87;1009.17) *	913.31 (759.37;1102.82) *#	1395.36 (1313.13;1600.00) *	1617.79 (1512.09;1809.04) *#
PC, u/mm^2	13.42 (12.87;13.56)	673.13 (549.12;704.52) *	804.02 (713.06;910.01) *	810.13 (804.82;1210.12) *	480.81 (370.37;560.74) *#	401.06 (372.67;411.77) *#	373.83 (297.03;545.56) *#
FC. u/mm^2	22.66 (13.56;26.82)	512.77 (281.37;711.65) *	1146.77 (866.81;1358.22) *	1685.27 (1523.84;2057.07) *	1821.02 (1817.34;1845.66) *#	2353.94 (2311.23;2401.00) *#	2467.89 (2413.88;3047.61) *#
UD, µm	0	575.00 (305.00; 780.60) *	735.00 (635.52;976.50) *	753.00 (372.00;882.50) *	294.00 (197.00;357.00) *#	242.00 (151.00;539.00) *#	238.50 (169.00;299.00) *#
TDI, c.u.	0	3.71 (3.00;4.00) *	3.57 (3.00;4.00) *	3.42 (3.00;4.00) *	3.00 (3.00;4.00) *	2.17 (1.00;3.00) *#	2.12 (1.00;3.00) *#

* – P<0.01 with Group 1, # - with Group 2; UD - ulcerous defect

Table 3.

MPO count and TNF-α count in the damaged area in the colon in study groups (Me (Q_1; Q_3))

Parameters	Group 1 (n=7)	Group 2 Day 2 (n=7)	Group 2 Day 4 (n=7)	Group 2 Day 6 (n=7)	Group 3 Day 2 (n=7)	Group 3 Day 4 (n=7)	Group 3 Day 6 (n=7)
MPO, u/mm^2	19.16 (0.00;19.16)	1241.37 (967.04;1486.59) *	938.69 (770.15;1109.19) *	775.86 (766.28;814.17) *	1053.64 (977.01;1091.95) *	498.08 (478.92;593.86) *#	287.35 (268.19;287.35) *#
TNF-α, u/mm^2	57.47 (38.31;76.63)	1321.83 (919.54;1475.09) *	1302.68 (1264.36;1321.83) *	752.87 (703.06;814.17) *	766.28 (670.49;957.85) *	727.96 (727.97;766.28) *#	210.72 (172.41;229.88) *#

* – P<0.01 with Group 1, # - with Group 2

Consequently, there was a massive decrease in DAI on Days 4 and 6 of the experiment (Table 1). Thus, DAI on Days 4 and 6 was significantly lower than in Group 2, which indicates partial restoration of the parameter.

In Group 3, histologic examination of the EC colonic wall in the place of the defect on Day 2 of the experiment showed ulcers in lamina propria and in the surface layers of the submucous membrane with venous and capillary plethora. Colonic mucosa was mildly edematic, the crypts were shortened and widened, and their epithelium was in a state of granular dystrophy (Fig.3).

On Day 4 of the experiment, we observed fully-epithelized areas of mucous lesion restoration with the initial formation of intestinal glands and crypts, focal granulocyte infiltration, and proliferation of juvenile fibroblasts (Fig.4). On Day 6 of the experiment, we recorded complete epithelization

Table 4.

LPP count in colonic mucosa lesion homogenate in the study groups (Me (Q_1; Q_3))

Parameters	Group 1 (n=7)	Group 2 Day 2 (n=7)	Group 2 Day 4 (n=7)	Group 2 Day 6 (n=7)	Group 3 Day 2 (n=7)	Group 3 Day 4 (n=7)	Group 3 Day 6 (n=7)
DC (h) u.o.i.	0.63 (0.55;0.65)	0.79 (0.75;0.81)*	0.78 (0.77;0.78)*	0.76 (0.75;0.77)*	0.77 (0.71;0.78)*	0.68 (0.63;0.68)#	0.70 (0.65;0.73)* #
KDCT (h) u.o.i.	0.06 (0.05;0.06)	0.08 (0.07;0.08)*	0.22 (0.21;0.22)*	0.09 (0.09;0.11)*	0.06 (0.06;0.09)	0.19 (0.18;0.19)* #	0.06 (0.05;0.07)#
SB (h) u.o.i.	0.01 (0.01;0.02)	0.03 (0.02;0.04)*	0.02 (0.02;0.05)*	0.05 (0.04;0.06)*	0.03 (0.02;0.04)*	0.01 (0.01;0.01)#	0.02 (0.01;0.03)#
DC (i) u.o.i.	0.34 (0.32;0.36)	0.38 (0.33;0.43)	0.55 (0.52;0.56)*	0.43 (0.43;0.45)*	0.38 (0.33;0.43)	0.51 (0.51;0.51)* #	0.41 (0.39;0.42)* #
KDCT (i) u.o.i.	0.31 (0.29;0.32)	0.72 (0.56;0.91)*	0.51 (0.51;0.57)*	0.48 (0.47;0.49)*	0.72 (0.56;0.91)*	0.42 (0.41;0.43)* #	0.42 (0.41;0.42)* #
SB (i) u.o.i.	0.01 (0.01;0.02)	0.07 (0.07;0.09)*	0.24 (0.21;0.31)*	0.11 (0.11;0.14)*	0.07 (0.07;0.09)*	0.01 (0.01;0.01)#	0.06 (0.05;0.08)* #
* –P<0.01 with Group 1, # - with Group 2. The parameters demonstrate LPP count in heptane (h) and isopropanol (i) phases of lipid extract.							

Table 5.

POM product counts in colonic mucosa lesion homogenate in the study groups (Me (Q_1; Q_3))

Parameters	Group 1 (n=7)	Group 2 Day 2 (n=7)	Group 2 Day 4 (n=7)	Group 2 Day 67 (n=7)	Group 3 Day 2 (n=7)	Group 3 Day 4 (n=7)	Group 3 Day 6 (n=7)
S_{POM}, au/mg (spont)	141.57 (141.28;144.18)	325.31 (251.18;348.01) *	214.59 (169.57;245.21) *	286.83 (165.86;297.74) *	166.74 (151.86;173.73) *#	181.91 (168.31;182.07) *	241.73 (238.92;261.63) *
S ADNPH, au/mg (spont)	131.25 (127.61;152.01)	294.78 (224.58;308.54) *	193.81 (165.47;222.84) *	268.31 (154.66;273.24) *	156.25 (132.91;163.51) #	166.57 (157.22;166.98) *	222.91 (219.25;242.86) *
S KDNPH, au/mg (spont)	12.16 (10.03;13.97)	30.53 (26.59;38.01) *	20.78 (14.39;22.35) *	18.52 (14.21;24.49) *	10.23 (8.94;10.49) #	14.07 (12.04;14.12) #	18.76 (18.76;18.83) *
S_{POM}, au/mg (ind)	266.20 (266.19;317.14)	321.71 (284.89;377.77)	416.51 (325.26;472.92) *	570.79 (526.85;638.48) *	266.02 (237.19;310.61)	328.36 (319.81;600.42) *	470.94 (328.39;470.94) *#
S ADNPH, au/mg (ind)	228.91 (228.81;237.95)	266.69 (264.71;314.21) *	338.86 (258.04;384.07) *	459.72 (422.91;521.53) *	217.64 (202.71;260.77) #	265.29 (253.29;492.93) *	403.12 (238.28;411.66) *#
S KDNPH, au/mg (ind)	37.31 (37.08;39.18)	54.36 (52.81;55.01) *	77.65 (59.35;79.95) *	108.05 (103.93;111.07) *	40.83 (39.84;48.37) *#	63.07 (48.51;107.49) *	59.27 (50.11;59.27) *#
* – P<0.01 with Group 1, # - with Group 2. POM product counts in spontaneous (spont) and induced (ind) modes.							

of the ulcerous defects, focal infiltration, and vast fields of proliferating fibroblasts, newly-formed fibers of connective tissue, and vessels in abundance (Fig.5).

Morphometric study of the cellular composition of the infiltrate in the colonic EC lesion against the background of the vitamin D3 therapy demonstrated that on Day 2, there was a significant decrease in NC, LC, EC, and PC, and an increase in HC and FC. On Day 4, there was a significant decrease in NC, LC, EC and PC, and an increase in FC.

On Day 6, we observed a significant decrease in NC, LC, EC, and PC, and an increase in HC and FC. On Days 2, 4, and 6 of the experiment, we found a decrease in the size of the ulcerous defect, and on Days 4 and 6 a decrease in TDI (Table 2). EC and HC were higher ($P<0.01$) on Day 4 than on Day 2, and on Day 6 higher ($P<0.01$) than on Day 2. FC was higher ($P<0.01$) on Day 4 than on Day 2, and on Day 6 than on Days 4 and 2. TDI was less on Days 4 and 6 ($P<0.01$) than on Day 2. During all periods of the study, morphometric parameters never reached the parameter values of the intact animals' group; the recovery was only partial.

The use of vitamin D3 in the EC therapy was associated with a decrease in the expression of MPO and TNF-α in the area of the ulcerous defect on Days 4 and 6 (Table 3). The MPO expression on Day 4 was lower ($P<0.01$) than on Day 2, and on Day 6 lower ($P<0.01$) than on Days 4 and 2. The TNF expression was lower ($P<0.01$) on Day 6 than on Days 4 and 2.

In the colonic mucosa lesion homogenate (in the heptane and isopropanol phases of the lipid extract), on Days 4 and 6 of EC with vitamin D3 therapy, there was a significant decrease in the counts of primary, secondary and end LPP (Table 4). In the heptane phase of the lipid extract, the primary LPP count on Days 4 and 6 was less($P<0.01$) than on Day 2. The count of the secondary LPP on Day 4 was higher than on Days 2 and 6. The count of the end LPP was less ($P<0.01$) on Day 4 than on Days 2 and 6. In the isopropanol phase of the lipid extract, the primary LPP count was higher ($P<0.01$) on Day 4 than on Days 2 and 6. The secondary LPP count was less ($P<0.01$) on Days 4 and 6 than on Day 2. The count of the end LPP was less ($P<0.01$) on Day 4 than on Days 2 and 6.

The use of the vitamin D3 rectal suppository led to a significant decrease in the total count of protein carbonyl derivatives (along with decreased counts of ADNPH and KDNPH) on Day 2. On Day 4, we observed a further decrease in the KDNPH count (Table 5). The total count of POM products and ADNPH count were higher ($P<0.01$) on Day 6 than on Days 4 and 2. The KDNPH count was higher ($P<0.01$) on Day 4 than on Day 2, and on Day 6 than on Days 4 and 2. In metal-induced mode, on Day 2, we recorded a decrease in the counts of ADNPH and KDNPH. On Day 6, there was a decrease ($P<0.01$) in total POM count, ADNPH count and KDNPH count. According to EC progression, in metal-induced mode, the total POM count and ADNPH count were higher ($P<0.01$) on Days 4 and 6 than on Day 2. The KDNPH count was higher ($P<0.01$) on Days 4 and 6 than on Day 2 of the experiment.

Thus, in cases of EC, there are specific clinical manifestations (loss of weight, loose stool with blood admixture) and morphological patterns, which is typical for IBDs. It makes it possible to apply the suggested model for further research of IBD pathogenesis and IBD experimental therapy.

There is an assumption that oxazolone is similar to haptene in its qualities. Haptene directs the immune response mostly through Th2-dependent way, which is accompanied by increased immunoglobulin (IgG, IgM) secretion and cytokine (IL-6, IL-8, TNF-α, etc.) secretion in blood. It results in leukocyte accumulation in the area of inflammation, damage of the colonic wall, and extension of the secondary alteration area.[28,29] The source of ROS that initiates lipid destruction, protein destruction, and accumulation of LPP and POM in the colonic wall is mostly neutrophils, monocytes/macrophages. Infiltration by the latter is a typical morphological sign of colitis.[30] IL-1, IL-6, TNF-α, and other anti-inflammatory cytokines intensify myelopoiesis and release of mature neutrophils and monocytes from the bone marrow and their migration to the inflammation site.[31] Endotheliocytes can also take part in ROS production due to eNOS activation, NO synthesis, and peroxynitrite synthesis.

In cases of EC with the use of original vitamin D3 rectal suppositories, a decrease in clinical manifestations and morphological signs of damage in the colonic wall can take place due to the vitamin D3 pleiotropic effect.

The correlation analysis showed the average and high strength of the relationship between the severity of clinical manifestations according to DAI and the following parameters: TDI, size of the ulcerous defect, HC, MPO count and TNF-α count in the damaged area (on Days 2, 4, and 6 of EC), PC (on Days 4 and 6 of EC), LC (on Day 6 of EC), and FC (on Day 6 of EC), as well as the primary, secondary and end LPP counts in heptane and isopropanol phases (peak on Days 2 and 4 of EC), and the counts of ADNPH and KDNPH in spontaneous and induced modes (peak on Days 2 and 4 of EC) (Table 6).

We believe that the obtained results are connected to several mechanisms of the vitamin D3 effect in cases of EC. First, the immunotropic effect of vitamin D3 is realized by the active influence of vitamin D3 metabolite calcitriol on T-lymphocyte proliferation and differentiation. It decreases Th1, Th17 count and increases Treg due to decreased synthesis of IL-1, IL-2, IL-6, IL-12, IL-17, IFN-γ, TNF-α, and increased synthesis of IL-10. Vitamin D3 inhibits macrophage migration and macrophage production of IL-1, IL-6, IL-12, as well as chemotaxis and neutrophil accumulation.(30) On the surface of dendritic cells, vitamin D3 inhibits the expression of TLR, CD40, CD80, CD83, and CD86, decreases secretion of IL-2 and IFN-γ by dendritic cells, and increases IL-10 synthesis.[32] It restricts the activity of the inflammation process in the colon and colonic tissue alteration.[33]

Second, vitamin D3 antioxidant effect is achieved directly through activation of transcriptional factor – nuclear factor erythroid 2-related factor 2, which is responsible for the regulation of antioxidant ferment expression, antioxidant ferment synthesis induction, and antioxidant enterocyte protection in conditions of OS.[21,28,33,34] Vitamin D3 indirect antioxidant effect is connected with a decrease in the infiltration of the damaged area by ROS-producer cells

(neutrophils and monocytes/macrophages) in conditions of restoring cooperation of immune-competent cell.

Table 6.

Correlation between DAI and other parameters in Group 3

Parameters	Group 3 Day 2	Group 3 Day 4	Group 3 Day 6
LC, u/mm^2	R=0.34	R=0.22	R=0.55*
NC, u/mm^2	R=0.20	R=0.24	R=0.18
EC, u/mm^2	R=0.24	R=0.15	R=0.15
HC, u/mm^2	R= - 0.58*	R= - 0.52*	R= - 0.56*
PC, u/mm^2	R= 0.41	R= 0.58*	R= 0.78*
FC, u/mm^2	R= - 0.38	R= - 0.35	R= - 0.55*
Ulcerous defect, μm	R=0.54*	R=0.58*	R=0.69*
TDI, c.u.	R=0.79*	R=0.78*	R=0.78*
MPO, u/mm^2	R=0.62*	R=0.67*	R=0.53*
TNF-α, u/mm^2	R=0.60*	R=0.59*	R=0.57*
DC (h), u.o.i.	R=0.72*	R=0.58*	R=0.72*
KDCT (h), u.o.i.	R=0.71*	R=0.82*	R=0.66*
SB (h), u.o.i.	R=0.52	R=0.17	R=0.88*
DC (i), u.o.i.	R=0.73*	R=0.75*	R=0.92*
KDCT (i), u.o.i.	R=0.81*	R=0.76*	R=0.88*
SB (i), u.o.i.	R=0.81*	R=0.31	R=0.72*
S_{PQM}, au/mg (spont)	R=0.71*	R=0.77*	R=0.89*
S ADNPH, au/mg (spont)	R=0.76*	R=0.68*	R=0.38
S KDNPH, au/mg (spont)	R=0.75*	R=0.86*	R=0.50
S_{PQM}, au/mg (ind)	R=0.86*	R=0.85*	R=0.81*
S ADNPH, au/mg (ind)	R=0.74*	R=0.81*	R=0.45
S KDNPH, AU/mg (ind)	R=0.73*	R=0.75*	R=0.37

** – P<0.01*

Third, vitamin D3 activates reparation processes in the damaged area of the colon in cases of EC. In coordination with specific nuclear receptors of colonic epithelial cells, vitamin D3 intensifies the expression of vinculin, zonulin, occludin and claudin – proteins that take part in the formation of epithelial cells.[16,34,35] Increases in histocyte and fibroblast count in the damaged area indicate active reparation processes in the colonic wall. Furthermore, inhibition of vascular-exudative and leucocyte reactions due to anti-inflammation and antioxidant effect activates the reparation process under the conditions of using vitamin D3.

Conclusion

In cases of oxazolone-induced EC, on Days 2, 4, and 6, we registered clinical and laboratory signs, an ulcerous defect in the damaged area of the colon, all of which are typical for IBD conditions. There was an increase in DAI (peak on Day 6) and TDI (peak on Day 2). We also found an increase in NC (peak on Day 2), LC (peak on Day 6), EC (peak on Day 2), PC (peak on Day 2), HC (peak on Day 2), and FC (peak on Day 2). There was an increase in MPO expression (peak on Day 2) and TNF-α expression (peak on Days 2 and 4). We observed increases in the primary, secondary, and end LPP counts and the early-phase and late-phase POM counts in spontaneous and induced modes. An administration of 1500ME vitamin D3 rectal suppositories every 12 hours for 6 days decreased the severity of clinical manifestations and DAI. It reduced the area of the ulcerous defect and decreased the TDI on Days 4 and 6 of the experiment. On the background of using vitamin D3 rectal suppositories, we found a decrease in NC, EC, LC, and PC in the damaged area and an increase in HC and FC on Days 2, 4, and 6 from the start of the experiment. Administration of D3 rectal suppositories decreased MPO expression and TNF-α expression on Days 4 and 6 of EC. In the damaged area of the colon, we observed a decrease in the counts of the primary, secondary, and end LPP on Days 4 and 6 of the experiment. We also documented a decrease in the POM count in spontaneous mode on Day 2 and on Day 6 in induced mode. The severity of EC clinical manifestations diminished, as did TDI, size of the ulcerous defect, MPO and TNF-α in the damaged area, and protein and lipid oxidative breakdown products.

We believe that the obtained results are essential for carrying out further research aimed at elaboration of the mechanism of the D3 effect in cases of IBD and at its possible clinical use.

Competing Interests

The authors declare that they have no competing interests.

References

1. Knyazev OV, Shkurko TV, Kagramanova AV, Veselov AV, Nikonov EL. [Epidemiology of inflammatory bowel disease. The current state of the problem (Literature review)]. Evidence-Based Gastroenterology. 2020;9(2):66–73. doi: 10.17116/dokgastro2020902166. [Article in Russian].
2. Mak WY, Zhao M, Ng SC, Burisch J. The epidemiology of inflammatory bowel disease: East meets west. J Gastroenterol Hepatol. 2020 Mar;35(3):380-389. doi: 10.1111/jgh.14872.
3. Dolgushina AI, Khusainova GM, Vasilenko AG, Kononets VA. [The prevalence of inflammatory bowel disease in the Chelyabinsk region]. Almanac of Clinical

Medicine. 2019;47(6):511-517. doi:10.18786/2072-0505-2019-47-066. [Article in Russian].
4. Tohari AM, Alhasani RH, Biswas L, Patnaik SR, Reilly J, Zeng Z, Shu X. Vitamin D Attenuates Oxidative Damage and Inflammation in Retinal Pigment Epithelial Cells. Antioxidants (Basel). 2019 Aug 24;8(9):341. doi: 10.3390/antiox8090341.
5. Kopecki Z, Yang G, Treloar S, Mashtoub S, Howarth GS, Cummins AG, Cowin AJ. Flightless I exacerbation of inflammatory responses contributes to increased colonic damage in a mouse model of dextran sulphate sodium-induced ulcerative colitis. Sci Rep. 2019 Sep 5;9(1):12792. doi: 10.1038/s41598-019-49129-6.
6. Sitkin SI, Vakhitov TY, Demyanova EV. [The microbiome, colon dysbiosis, and inflammatory bowel disease: when function is more important than taxonomy]. Almanac of Clinical Medicine. 2018;46(5):396–425. doi:10.18786/2072-0505-2018-46-5-396-425. [Article in Russian].
7. Ungaro R, Mehandru S, Allen PB, Peyrin-Biroulet L, Colombel JF. Ulcerative colitis. Lancet. 2017 Apr 29;389(10080):1756-1770. doi: 10.1016/S0140-6736(16)32126-2.
8. Yokoyama Y, Kamikozuru K, Nakamura S. Granulomonocytapheresis as a cell-based therapy in an ulcerative colitis patient complicated by aminosalicylate-induced severe lymphocytopenia and pneumonia. Cytotherapy. 2016 Sep;18(9):1234-6. doi: 10.1016/j.jcyt.2016.05.016.
9. Ivashkin VT, Shelygin YA, Khalif IL, Belousova EA. [Clinical recommendations of the Russian gastroenterological association and the association of coloproctologists of Russia for the diagnosis and treatment of ulcerative colitis]. Coloproctology. 2017;1(59):6-30. [Article in Russian].
10. Šimoliūnas E, Rinkūnaitė I, Bukelskienė Ž, Bukelskienė V. Bioavailability of Different Vitamin D Oral Supplements in Laboratory Animal Model. Medicina (Kaunas). 2019 Jun 10;55(6):265. doi: 10.3390/medicina55060265.
11. Yamamoto E, Jørgensen TN. Immunological effects of vitamin D and their relations to autoimmunity. J Autoimmun. 2019 Jun;100:7-16. doi: 10.1016/j.jaut.2019.03.002.
12. Bakke D, Sun J. Ancient Nuclear Receptor VDR With New Functions: Microbiome and Inflammation. Inflamm Bowel Dis. 2018 May 18;24(6):1149-1154. doi: 10.1093/ibd/izy092.
13. Harrison SR, Li D, Jeffery LE, Raza K, Hewison M. Vitamin D, Autoimmune Disease and Rheumatoid Arthritis. Calcif Tissue Int. 2020 Jan;106(1):58-75. doi: 10.1007/s00223-019-00577-2.
14. Liu J, Wang W, Liu K, Wan D, Wu Z, Cao Z, Luo Y, Xiao C, Yin M. Vitamin D receptor gene polymorphisms are associated with psoriasis susceptibility and the clinical response to calcipotriol in psoriatic patients. Exp Dermatol. 2020 Dec;29(12):1186-1190. doi: 10.1111/exd.14202.
15. Del Pinto R, Ferri C, Cominelli F. Vitamin D Axis in Inflammatory Bowel Diseases: Role, Current Uses and Future Perspectives. Int J Mol Sci. 2017 Nov 7;18(11):2360. doi: 10.3390/ijms18112360.
16. Naderpoor N, Mousa A, Fernanda Gomez Arango L, Barrett HL, Dekker Nitert M, de Courten B. Effect of Vitamin D Supplementation on Faecal Microbiota: A Randomised Clinical Trial. Nutrients. 2019 Nov 27;11(12):2888. doi: 10.3390/nu11122888.
17. Simonyan EV, Osikov MV, Boyko MS, Bakeeva AE. Remedy with vitamin D3 for the treatment of ulcerative colitis in the form of rectal suppositories. Patent RU, No. 2709209. 2019. Bull. #35.
18. Osikov MV, Boyko MS, Simonyan EV, Ushakova VA. [Immunotropic effects of vitamin D3 in original rectal suppositories in experimental ulcerative colitis]. Medical Immunology (Russia). 2021;23(3):497-508. doi: 10.15789/1563-0625-IEO-2176. [Article in Russian].
19. Directive 2010/63/EU of the European Parliament and of the Council of September 22, 2010, on the Protection of Animals Used for Scientific Purposes 2010. Official Journal of the European Union. L 276/33. Available from: https://eur-lex.europa.eu/eli/dir/2010/63/oj.
20. Hoving JC, Keeton R, Höft MA, Ozturk M, Otieno-Odhiambo P, Brombacher F. IL-4 Receptor-Alpha Signalling of Intestinal Epithelial Cells, Smooth Muscle Cells, and Macrophages Plays a Redundant Role in Oxazolone Colitis. Mediators Inflamm. 2020 Jan 17;2020:4361043. doi: 10.1155/2020/4361043.
21. Osikov MV, Boyko MS, Simonyan EV. [The severity of the acute phase reaction to the use in experimental ulcerative colitis under D3 conditions in original rectal suppositories]. Pathological Physiology and Experiment. 2021;65(4):80–88. doi: 10.25557/0031-2991.2021.04.80-88. [Article in Russian].
22. Kim JJ, Shajib MS, Manocha MM, Khan WI. Investigating intestinal inflammation in DSS-induced model of IBD. J Vis Exp. 2012 Feb 1;(60):3678. doi: 10.3791/3678.
23. Yao J, Lu Y, Zhi M, Hu P, Wu W, Gao X. Dietary n-3 polyunsaturated fatty acids ameliorate Crohn's disease in rats by modulating the expression of PPAR-γ/NFAT. Mol Med Rep. 2017 Dec;16(6):8315-8322. doi: 10.3892/mmr.2017.7673.
24. Volchegorskiĭ IA, Nalimov AG, Iarovinskiĭ BG, Lifshits RI. [Comparison of various approaches to the determination of the products of lipid peroxidation in heptane-isopropanol extracts of blood]. Vopr Med Khim. 1989 Jan-Feb;35(1):127-31. [Article in Russian].
25. Lvovskaya EI, Volchegorsky IA, Shemyakov SE, Lifshits RI. [Spectrophotometric determination of LPO end products]. Voprosy Meditsinskoi Khimii. 1991;4:92–93. [Article in Russian].
26. Dubinina EE. Products of oxygen metabolism in the functional activity of cells (life and death, creation and destruction). Physiological and clinical-biochemical aspects. SPb.: "Medical press", 2006. [In Russian].
27. Fomina MA. A method for a comprehensive assessment of the content of products of oxidative modification of proteins in tissues and biological fluids: Guidelines. Ryazan, 2014. [In Russian].

***Corresponding author:** *Margarita S. Boyko. South Ural State Medical University, Chelyabinsk, Russia. E-mail: ri-tochka9@list.ru*

28. Larabi A, Barnich N, Nguyen HTT. New insights into the interplay between autophagy, gut microbiota and inflammatory responses in IBD. Autophagy. 2020 Jan;16(1):38-51. doi: 10.1080/15548627.2019.1635384.
29. Lynch WD, Hsu R. Ulcerative Colitis. 2021 Jun 18. In: StatPearls [Internet]. Treasure Island (FL): StatPearls Publishing; 2022 Jan–. PMID: 29083748.
30. Tian T, Wang Z, Zhang J. Pathomechanisms of Oxidative Stress in Inflammatory Bowel Disease and Potential Antioxidant Therapies. Oxid Med Cell Longev. 2017;2017:4535194. doi: 10.1155/2017/4535194.
31. De Schepper S, Stakenborg N, Matteoli G, Verheijden S, Boeckxstaens GE. Muscularis macrophages: Key players in intestinal homeostasis and disease. Cell Immunol. 2018 Aug;330:142-150. doi: 10.1016/j.cellimm.2017.12.009.
32. Murdaca G, Tonacci A, Negrini S, Greco M, Borro M, Puppo F, Gangemi S. Emerging role of vitamin D in autoimmune diseases: An update on evidence and therapeutic implications. Autoimmun Rev. 2019 Sep;18(9):102350. doi: 10.1016/j.autrev.2019.102350.
33. Teixeira TM, da Costa DC, Resende AC, Soulage CO, Bezerra FF, Daleprane JB. Activation of Nrf2-Antioxidant Signaling by 1,25-Dihydroxycholecalciferol Prevents Leptin-Induced Oxidative Stress and Inflammation in Human Endothelial Cells. J Nutr. 2017 Apr;147(4):506-513. doi: 10.3945/jn.116.239475.
34. Fakhoury HMA, Kvietys PR, AlKattan W, Anouti FA, Elahi MA, Karras SN, Grant WB. Vitamin D and intestinal homeostasis: Barrier, microbiota, and immune modulation. J Steroid Biochem Mol Biol. 2020 Jun;200:105663. doi: 10.1016/j.jsbmb.2020.105663.
35. Charoenngam N, Holick MF. Immunologic Effects of Vitamin D on Human Health and Disease. Nutrients. 2020 Jul 15;12(7):2097. doi: 10.3390/nu12072097.