

Clinical Research

Efficacy and Safety of Tocilizumab in Patients with Severe Systemic Juvenile Idiopathic Arthritis

Ekaterina I. Alekseeva, PhD, ScD^{1,2*}, Rina V. Denisova, PhD¹,
Saniya I. Valieva, PhD¹, Tatyana M. Bsarova, PhD¹,
Kseniya B. Isaeva, PhD¹, Evgeniya G. Chistyakova, PhD¹,
Tatyana V. Sleptsova, PhD¹, Elena V. Mitenko¹

¹Scientific Centre of Children Health of RAMS, Moscow, Russian Federation

²I.M. Sechenov First Moscow State Medical University, Moscow, Russian Federation

Abstract

It has been observed that 10-20% of children with juvenile idiopathic arthritis (JIA) have a characteristically wide range of extra-articular manifestations. The treatment of systemic JIA with glucocorticoids and immunosuppressants has not always been effective. Significantly, interleukin-6 has been found to play an important role in the development of extra-articular manifestations and complications of the disease. Inhibition of this cytokine appears to be a promising therapeutic approach. The article presents the results of research on the effectiveness and safety of tocilizumab treatment in 39 patients with severe systemic JIA, refractory to standard immunosuppressive therapy. Tocilizumab therapy is characterized by high efficacy and safety. After six months of treatment, 50% of patients were recorded as having inactive disease status, while 57% of patients had no symptoms of the disease after 12 months. Adverse events manifested included mild to moderately severe infections, leukopenia and neutropenia. IJBM 2011; 1(4):190-198. © 2011 International Medical Research and Development Corporation. All rights reserved.

Key words: juvenile idiopathic arthritis, extra-articular manifestations, interleukin-6, tocilizumab therapy

Introduction

In 10-20% of children having JIA, a wide range of extra-articular manifestations such as fever, febrile, myopericarditis, pneumonitis and polyserositis was noted [1]. Despite the advances in modern medicine, treatment of the systemic JIA variant with glucocorticoids and immunosuppressants has not always proved effective [1-3]. In 50% of patients, progressively destructive changes in the joints, with recurring extra-articular manifestations, have been steadily increasing the disability level. Most children with JIA take oral, intravenous or intra-articular

corticosteroids. However, glucocorticoids do not control the disease, prevent the progression of cartilage bone destruction or reduce disability in patients, and their prolonged use leads to severe irreversible effects, particularly, short stature, delayed puberty, adrenal insufficiency, osteoporosis and hormone-dependence [1-3].

Interleukin 6 (IL-6), one of the central cytokines, has been discovered to play a leading role in the development of the systemic JIA variant. When excess IL-6 is produced, extra-articular manifestations such as fever and thrombocytosis are noted [4, 5]. IL-6 stimulates the production of the inflammatory proteins by hepatocytes (CRP, amyloid A, haptoglobin, fibrinogen), and competitively inhibits the synthesis of albumin and transferrin [6]. One of the extra-articular manifestations of severe JIA is the anemia which develops during IL-6 stimulated secretion of hepcidin by the hepatocytes. Hepcidin decreases the iron absorption in the intestine and inhibits its release from the macrophages, which is the

*Corresponding author: Prof. Ekaterina I. Alekseeva, PhD, ScD, Scientific Centre of Children Health of RAMS, 2/62, Lomonosov avenue, 119991, Moscow, Russian Federation.

Tel/Fax: 7-499-1340297

E-Mail: alekatya@yandex.ru

cause of iron deficiency necessary for erythropoiesis [7-10]. In normal concentrations, IL-6 enhances the synthesis of the adrenocorticotrophic hormone and cortisol, as well as the production of the growth hormone and procalcitonin [10, 11]. However, at higher concentrations, IL-6 blocks the production of these hormones, which leads to fatigue, sleepiness, depression, cognitive disorders and retarded growth in children with JIA [10-12], as the activity of IL-6 is also connected with the development of amyloidosis associated JIA. Thus, the inhibition of IL-6 is very important in the treatment of the systemic JIA variant. Tocilizumab was synthesized for this purpose. Tocilizumab (Actemra[®], F. Hoffmann-La Roche, Switzerland) is a humanized monoclonal antibody to the IL-6 receptor [13]. The drug is approved in Europe, U.S.A. and Japan for the treatment of rheumatoid arthritis, particularly the polyarticular and systemic variants of JIA [14, 15]. Based on the positive results of clinical studies on the efficacy and safety of tocilizumab therapy, the drug has been registered for the treatment of the systemic variant of JIA [16-23].

The study by Yokota S, Imagawa T, et al., included children between 2 and 19 years. The study was conducted at eight medical centers in Japan, in three phases, namely a 6-week open phase, a 12-week, double-blind, randomized, placebo-controlled phase, and a 48-week open phase [19]. The second blind randomized phase included patients with a 30% improvement on the criteria of the American College of Rheumatology (ACR) with serum CRP values less than 5 mg/L after the first open phase. Patients randomized to the first group were treated with tocilizumab, whereas those belonging to the second were given a placebo. The third open phase included children who did not drop out of the first and second phases of the study. In all the three phases, the drug was administered intravenously at a dose of 8 mg/kg, every two weeks.

Efficacy of the treatment was evaluated by a system of pediatric criteria ACRpedi [24] involving parental estimate of the patient's general health, physician's assessment of the disease activity on the visual analog scale (VAS), questionnaire relating to the functional ability, namely Childhood Health Assessment Questionnaire (CHAQ), the number of joints with active arthritis, the number of joints with restricted movement and ESR. Systemic manifestations of the disease included fever, rash, lymphadenopathy, cervical, axillary and inguinal lymph nodes, splenomegaly, hepatomegaly, serositis, and were estimated by counting the total number (from 0 to 8). The study included 56 children with the systemic variant of JIA. All the children had been treated previously with glucocorticoids, mainly the immunosuppressive drugs, methotrexate and cyclosporin. Patients had a mean level of JIA activity with ESR of 44.5 (8-125.0) mm/h and CRP of 43.5 (16-190) mg/L. They also exhibited several systemic manifestations ranging from 0 to 3. Febrile fever was reported in 49 (88%) children.

Analysis of the effectiveness of the tocilizumab

therapy in 56 children tested in the primary open-phase testified revealed about 30%, 50% and 70% improvement in 51 (91%), 48 (86%) and 38 (68%) children, respectively. After two weeks, the value of serum CRP was less than 5 mg/L in 48 (86%) patients. However, after six weeks of treatment with tocilizumab, only 44 (79%) patients had a combination of two criteria, namely, ACRpedi30 and a CRP concentration in the serum of less than 5 mg/L. In the initial open phase, the number of children possessing more than one manifestation of systemic JIA had decreased from 49 (88%) to 33 (59%).

At the end of the double-blind phase of the 20 children treated with tocilizumab, 30% improvement and reduction in the serum CRP concentration was observed in 16 (80%) and 4 (17%) patients receiving the placebo. Improvement criteria ACRpedi50 and 70 were observed in 16 (80%) and 15 (75%) of the cases treated tocilizumab, and in 4 (17%) and 3 (13%) of 23 children treated with the placebo [19].

In the final open phase involving 50 children, 48 (96%) continued to be treated with tocilizumab. After 48 weeks, 30%, 50%, 70% improvement criteria ACRpedi were recorded in 47 (98%), 45 (94%) and 43 (90%) children, respectively. The ESR value decreased to 3 (0-12) mm/h (at 93.2%: 100%-78.6%), serum concentrations of CRP dropped to 0.1 (0-2) mg/L (99.7% to 100%-95.1%).

Significantly, the hemoglobin content in the RBCs was noted to increase from 111 (74-151) to 124 (73-179) g/L, while the platelet count decreased from 418 (168-862) to $302 \times 10^9/L$ (131-556).

Throughout the study, all the patients were treated with glucocorticoids, on a steady dose. Later, the dosage was reduced by 30% in 33 (69%) and 50% in 22 (46%) out of 48 patients.

Improvement was seen on resuming the tocilizumab infusion in patients who had not completed treatment in the second phase and they were included in the third phase of the study [19]. On assessing the safety of tocilizumab therapy in a Phase III study, 13 serious adverse events (AE), were observed including bronchitis, gastroenteritis, anaphylaxis. The most frequent mild AE observed in 56 patients were nasopharyngitis in 33 patients (59%), infection of the upper respiratory tract in 19 cases (34%), gastroenteritis in 16 (29%) and bronchitis in 14 (25%). An increase in the ALT concentration was observed in 16 patients (29%), AST in 12 cases (21%) and LDG in 10 (18%) children. Four patients with bronchitis and gastroenteritis were given antibiotic therapy. The results of the research on the effectiveness and safety of long-term treatment with tocilizumab in 67 children with the systemic variant of JIA (29 boys, 38 girls) were noted to be very interesting. The analysis was done on 56 children as described in the Phase III clinical study, and 11 patients were treated with tocilizumab in the clinical Phase II study [17]. The median duration of treatment was 185 weeks of tocilizumab therapy (3.5 years), with a maximum of 324 weeks (6 years), although 53 (79%) of 67 patients

continued the tocilizumab therapy for the fourth year. The incidence of serious AE during the entire observation period was found to be 35.5 per 100 patient-years, and of severe infections it was 13.6 per 100 patient-years. The most frequently occurring AE were nasopharyngitis, gastroenteritis, and infections of the upper respiratory tract. Within three years of observation, no cases of opportunistic infections, cancer and autoimmune diseases, including deaths were identified. Improvement criteria ACRpedi 30, 50, 70 and 90 were recorded in 100%, 98%, 93% and 64% of patients, respectively, after 96 weeks (n=58), and in 96%, 96%, 88% and 73% of patients after 168 weeks (n=51). Significantly, all the patients were treated with glucocorticoids. The prednisolone dose was reduced by 50% after 168 weeks of therapy in 77% of the patients.

Interestingly, in 8 children, tocilizumab therapy was canceled due to the development of long-term remission, but 6 of them noted exacerbation after 7-82 weeks after the last infusion of the tocilizumab, which was the basis for the resumption of therapy [17].

Several studies have examined the effect of tocilizumab on the bone and cartilage process of joint damage in children with the systemic variant of JIA [20, 22, 25]. The study conducted by Y. Inaba et al., included 20 children [25]. All the patients were given intravenous tocilizumab 8 mg/kg, every the weeks, and observed for an average of 41 months (11-82). The number of joints with active arthritis during the treatment decreased from 3.3 (0-12) to 0.3 (0-4), the number of leukocytes decreased from 13.8 to $6.4 \times 10^3/\text{mm}^3$, the ESR value dropped from 44 to 3 mm/h, and serum concentrations of CRP were lowered from 6.7 to 0.01 mg/dL. X-ray examination of all the major joints showed clear improvement. Improvement was characterized by a decrease in the frequency of the occurrence of periarticular osteoporosis (from 84% to 30%), thickening of the soft tissues (from 45 to 9%) and narrowing of the joint cracks, subchondral cysts and bone erosions. Only one patient continued to have active arthritis in four joints, and a progression of destructive changes was observed. The results suggest the inhibition of the progression of destructive bone and cartilage changes in the joints of children with JIA, treated with tocilizumab.

Material and Methods

In a retrospective observational study, patients with the systemic variant of JIA, treated with tocilizumab between June 2009 and January 2011 in the Rheumatology Department, Science Center for Children's Health of RAMS were followed. The use of tocilizumab in all the cases was approved by the local ethics committee. Prior to treatment, written consent was taken from the parents of the children, while children aged 14 and older gave written informed consent themselves.

The results of the treatment of 39 children (18 girls

and 21 boys) aged 7.5 (6, 9) years (Me (25, 75)) were given in this analysis. The average duration of the illness before beginning tocilizumab therapy was 4 (2.2 to 6) years. A diagnosis of the systemic variant of JIA was made based on the diagnostic ILAR criteria (International League of Associations for Rheumatology) [1]. All patients underwent standard clinical and laboratory examination. Control of the hemoglobin level, including the number of erythrocytes, platelets, leukocytes, leukocyte, ESR, the concentration of urea, creatinine, uric acid, bilirubin, transaminases, serum and clinical urinalysis was performed once every two weeks. Blood pressure (BP) was checked on a daily basis.

The number of swollen, painful joints, joints with limitation of motion, the number of systemic manifestations of the disease, and the serum concentrations of CRP were determined on a monthly basis. The effectiveness of the therapy was evaluated according to the criteria to improve the ACR, namely ACR30, ACR50, ACR70, ACR90. The criteria included a parental assessment of the patient, the general health of the patient, a physician assessment of the disease activity using VAS, the functional ability on the CHAQ, the number of joints with active arthritis, the number of joints with limitation of motion and the ESR value.

The efficiency targets of therapy included inactive frequency of reaching the stage of the disease and drug-disease remission. Inactive phase of the disease was established in the absence of active synovitis, systemic manifestations of the disease, normal parameters of ESR and serum CRP, as well as the absence of disease activity on the overall assessment by the doctor (on VAS). Remission was understood to have set in if the disease was inactive for six consecutive months after the initiation of therapy. At the time of therapy initiation most children exhibited articular syndrome which was polyarticular in nature (Table 1). All the patients revealed extra-articular manifestations of the disease, namely fever in 95% (37), carditis in 6% (22), lymphadenopathy in 80% (31), maculopapular rash in 30% (12) and hepatomegaly in 50% (19) of the patients. The number of systemic manifestations per patient was 2.4 (1.5, 3) (Table 1, Fig. 1). High clinical disease activity was accompanied by a general inflammatory reaction. This included CBC which showed up as hypochromic anemia in 85% (33), neutrophilic leukocytosis in 65% (25) and thrombocytosis in 71% (28). The median ESR was more than three times the normal value and serum concentrations of CRP increased up to 9 times (see Table 1). Thus, at the beginning of therapy all the patients with JIA showed active joint syndrome, severe systemic manifestations and high laboratory parameters of the disease activity with increasing disability.

Previous therapy: Prior to the tocilizumab treatment all the patients were treated with antirheumatic therapy, in various modes. In the initial stages of the disease (based on the place of residence in the territorial health care facility) 54% (21) children were prescribed oral

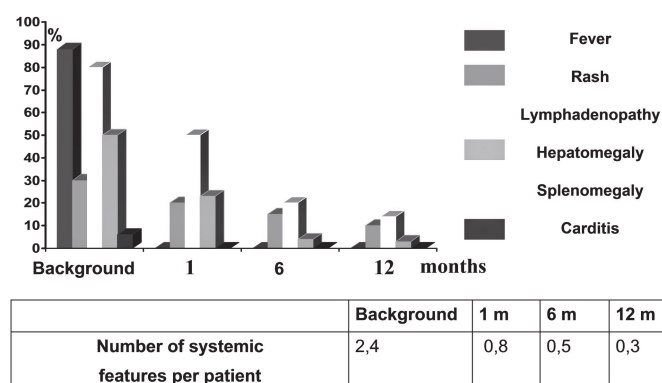
Table 1

Characterization of patients with the systemic variant of JIA included in the study

Index	Value
number of swollen joints	8 (2;13)
number of joints with active arthritis	8 (4;14)
number of joints motion limitation	9 (3; 16)
number of systemic manifestations per one patient	2,4 (1,5; 3)
ESR, mm/h	30 (23; 55)
platelets, x10 ⁹ /L	560 (455; 655)
hemoglobin, g/L	94 (89; 99)
serum CRP, mg%	7.3 (5; 14)

Figure 1

Dynamics of systemic manifestations in patients with systemic variant of JIA treated with tocilizumab



prednisolone at a dose of 10 to 30 mg / day. All the children were on methylprednisolone pulse therapy at a dose of 10-30 mg/kg initially, 29 (75%) were using a local glucocorticoid therapy from 1 to 10 times a year, 17 (44%) were on anti-TNF-therapy and 16 (41%) were on anti-B cell therapy with rituximab. All the children were on nonsteroidal antiinflammatory drugs (NSAIDs).

Background therapy: Tocilizumab was administered in patients receiving immunosuppressive drugs (Table 2).

The administration scheme of tocilizumab: Tocilizumab was administered intravenously, once every two or four weeks at a dose of 8-10 mg/kg per infusion. All the children within one or two months of receiving the drug every two weeks had the interval increased to four weeks between doses. Infusions were performed for one hour, at the rate of 10 ml/h for the first 15 minutes, and then increased to 130 ml/hour.

Analysis of the efficacy was done after one month. The results indicated improvement in 36 children by two months, in 28 children by 3 months, in 20 children by 6 months, in 18 children by 9 months and in 16 children by the end of a year.

Table 2

Characterization of the background therapy in patients with the systemic variant of JIA included in the study

Drug	Dose (Me (25; 75))	Number of children
methotrexate, mg/m ² /week	20 (15; 24)	39
cyclosporine, mg/kg/day	4 (4; 4)	29
prednisolone, mg/day	12.5 (8; 12)	21
NSAIDs	-	39

Statistical data processing was performed using the program STATISTICA 6.0 (StatSoft Inc., USA). Quantitative characters are shown as median (25, 75 percentiles). Changes in the quantitative traits during the treatment were evaluated using the Wilcoxon test conjugate pairs. Statistically significant differences were considered at p<0.05.

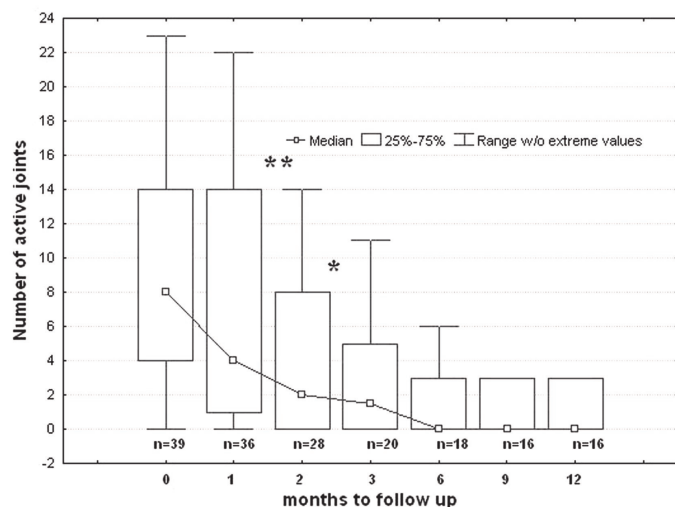
Results and discussion

Tocilizumab treatment ensured reliability and marked improvement of the systemic manifestations, as well as clinical and laboratory parameters of the disease activity.

Within one month after initiation of therapy, patients showed a significant decrease in the systemic manifestations of JIA (Fig. 1). Carditis one of the serious manifestations of the extra-articular manifestations of JIA, disappeared in all the patients. It also significantly reduced the frequency of skin rash, from 12 (30%) to 7 (20%) of the cases. Dimensions of the liver and spleen were normalized in 54% (18) patients. After the first infusion of tocilizumab, no temperature rises were observed in all the patients (Fig. 2).

Figure 2

Dynamics of the number of joints with active arthritis in patients with systemic variant of JIA, treated with tocilizumab



Note: ** - $p < 0.1$, * - $p < 0.001$

After observation of 16 patients over a year, lymphadenopathy persisted in 3 patients (18%), rash in 2 cases (12%) and hepato/splenomegaly in 1 patient (6%). At the end of one year of observation, the number of systemic manifestations per patient was 0.3 (see Figs. 1 and 2).

Analysis of the dynamics of the activity of the joint syndrome in the fourth week of treatment revealed a significant decrease in the number of joints with active arthritis as seen in the following data, a decrease from 8 (4, 14) to 4 (1, 14), $p < 0.01$. By the 12th month the rate was 0 ((0, 3), $p < 0.001$) (Fig. 2). The same trend was observed in the joints with the dysfunction. That number too significantly dropped after four weeks of treatment (Fig. 3). By the end of one year's observation the median number of joints with dysfunction decreased 9 times ($p < 0.001$).

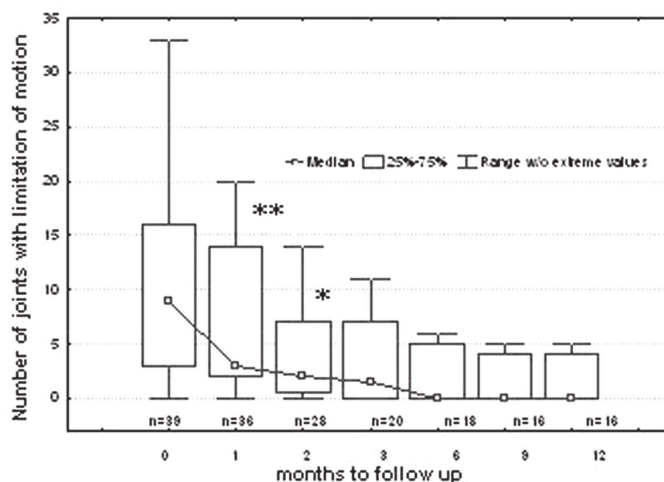
Along with the decrease in the number of joints with active arthritis, as well as the joints with limitation of function, a significant improvement in functional capacity of the affected joints was noted (Fig. 4). After four weeks of treatment, the tocilizumab index functional impairment by CHAQ questionnaire decreased significantly from 2.0 (1.3, 2.75) to 1.0 (0.6; 1.4), $p < 0.001$.

Tocilizumab therapy also influenced the laboratory parameters of the disease activity, showing significant improvement in the hemoglobin levels (Fig. 5), low platelet counts, ESR, serum CRP and the normalization of these indices by the second month of treatment (Fig. 6-8).

Evaluating the effectiveness of therapy (criteria ACRped) by one month of tocilizumab therapy showed 30% improvement in 82% of the patients, 50% improvement in 50% of the cases and 70% improvement in 27% of the patients.

Figure 3

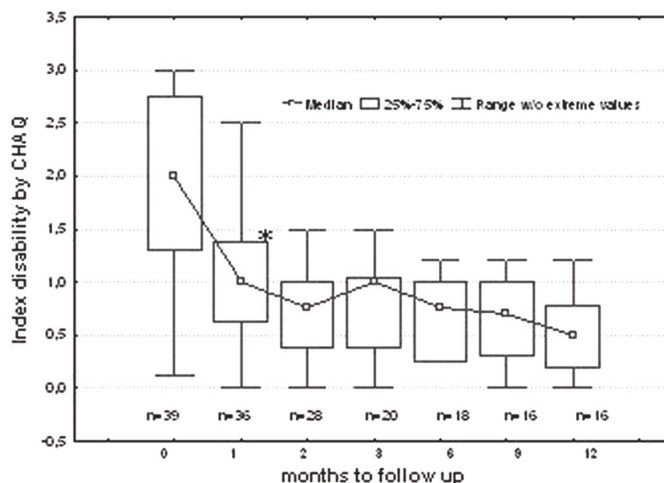
Dynamics of the number of joints with limitation of motion in patients with systemic variant of JIA, treated with tocilizumab



Note: ** - $p < 0.1$, * - $p < 0.001$

Figure 4

Dynamics of the index of functional failure in patients with systemic variant of JIA, treated with tocilizumab



Note: * - $p < 0.001$

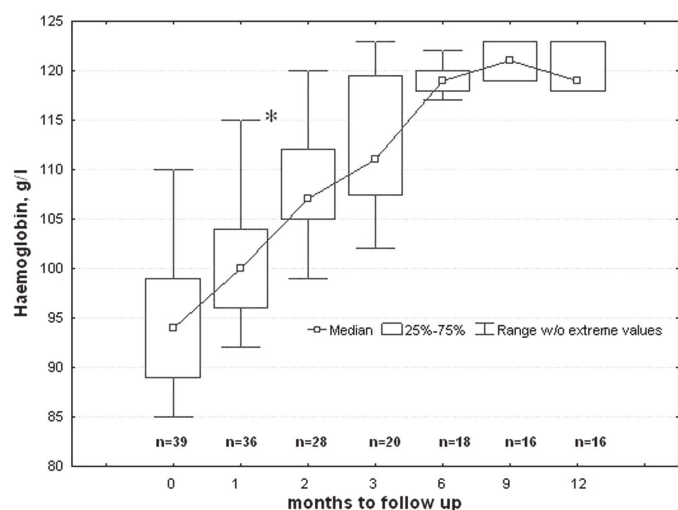
After six months of treatment, all the children maintained improvement criteria ACR30 while 69% recorded a rate of ACR70. After a year of therapy, 50% and 70% improvement, respectively, was observed in 85% and 78% of patients (Fig. 9).

In general, the effectiveness of tocilizumab after more than six months of treatment was characterized by the achievement of inactive disease status in 50% (9 of 16) patients after one year in 57% (8 of 14) patients.

Safety assessment of tocilizumab treatment was performed by registered AE, laboratory parameters, based on the results of the physical examination (BP, HR),

Figure 5

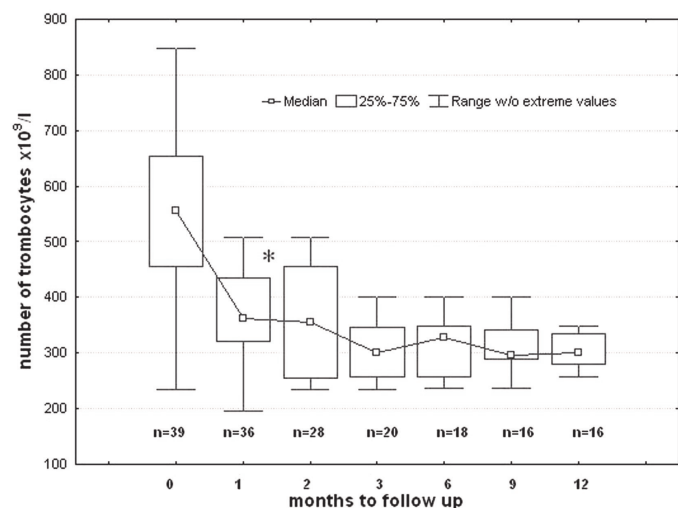
Dynamics of hemoglobin level in red blood cells in patients with systemic variant of JIA, treated with tocilizumab



Note: * - $p < 0.001$

Figure 6

Dynamics of the number of platelets in the peripheral blood of patients with systemic variant of JIA, treated with tocilizumab



Note: * - $p < 0.001$

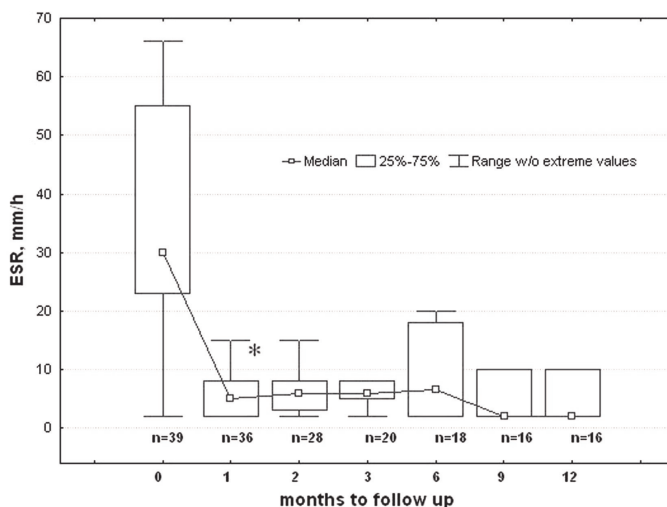
and ECG. AE were evaluated in all the patients enrolled in the study, who received at least one infusion.

Tocilizumab treatment was well tolerated and most AE were mild or moderate, reversible, not limiting the course of the treatment. Infusion reactions were noted. Registered AE were differentiated into two groups, namely infectious disorders and laboratory parameters (Table 3).

Among the infectious AE reported, cellulitis was seen in 1 patient, exacerbation of herpes infection in 2 cases and acute focal pneumonia in 1 patient. Cellulitis

Figure 7

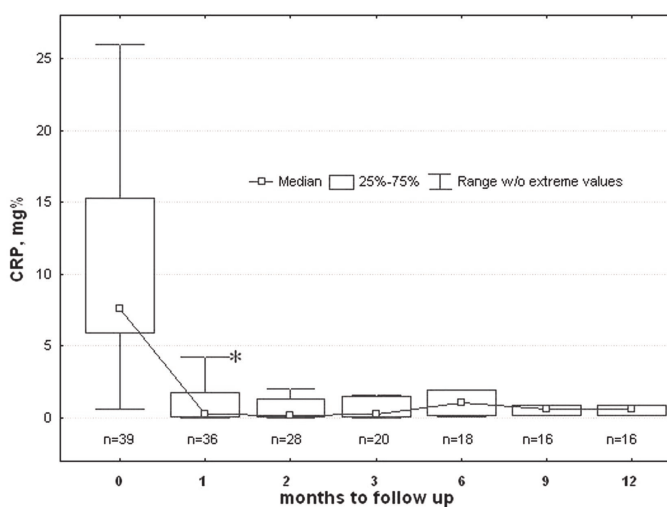
Dynamics in the erythrocyte sedimentation rate in patients with systemic variant of JIA, treated with tocilizumab



Note: * - $p < 0.001$

Figure 8

Dynamics of serum CRP level in patients with systemic variant of JIA, treated with tocilizumab

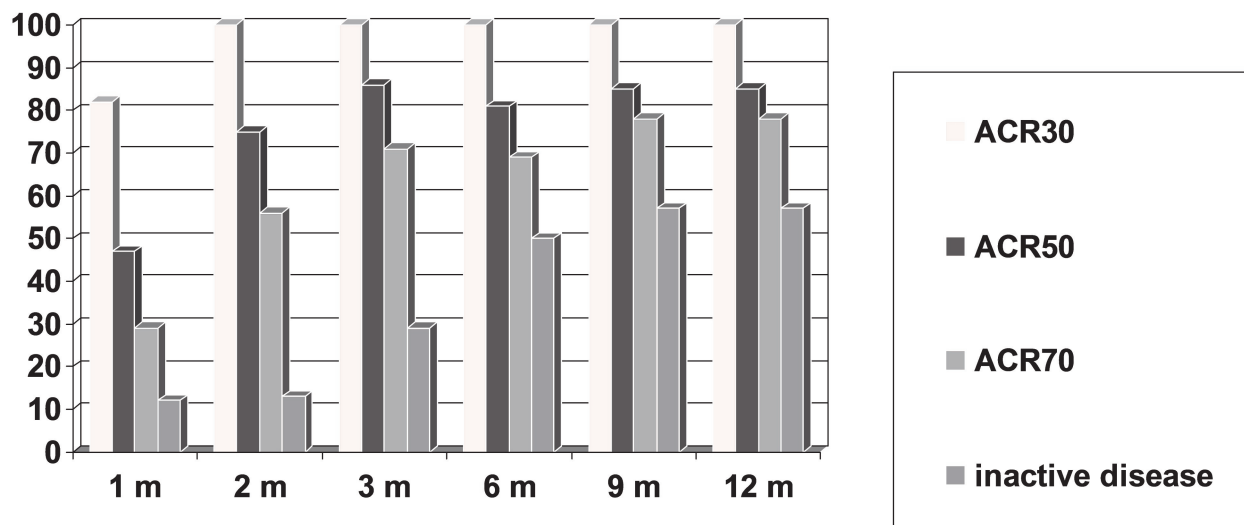


Note: * - $p < 0.001$

developed on the fifth day after the first injection of tocilizumab, concomitant therapy included methotrexate dose of 15 mg/m² and cyclosporine at 4 mg/kg. Antibiotic therapy provided complete relief of cellulitis without complications. Acute lobular pneumonia was recorded after the third administration of tocilizumab (9 weeks after initiation of therapy). Patient also received methotrexate at a dose of 15 mg/m². Antimicrobial treatment of pneumonia provided relief without complications. Aggravation of herpetic infection (2 cases) was not considered serious AE. Among the AE with the laboratory parameters, neutropenia was most frequently observed in the first few days after

Figure 9

The efficacy of tocilizumab therapy according the ACR pediatric criteria in patients with systemic variant of JIA

**Table 3**

Adverse events in patients on tocilizumab therapy

Adverse events	Patients n (%)
<i>Laboratory parameters:</i>	
neutropenia	21 (53%)
thrombocytopenia	1 (3%)
increase in alkaline phosphatase	1 (3%)
<i>Infectious disorders:</i>	
cellulitis	1 (3%)
exacerbation of herpes infection	2 (6%)
acute focal pneumonia	1 (3%)

administration of the tocilizumab, in 53% (21) of the patients. In 13 patients, the absolute neutrophil count decreased $<1,000$ in $1 \mu\text{L}$, whereas in 2 patients it was 500 per $1 \mu\text{L}$.

On identifying neutropenia, daily monitoring was conducted until neutrophil recovery occurred within weeks after the infusion. By reducing the number of neutrophils $<1.0 \times 10^9/\text{L}$ patients received the colony-stimulating factor (G-CSF) filgrastim, at a dose of 5 mg/kg, with a positive effect. All the cases of neutropenia were associated with tocilizumab infusion. None of them were accompanied by infection and it was not a cause of treatment discontinuation.

The development of thrombocytopenia was observed in one patient after 11 months of therapy. Two weeks after the regular drug administration, the platelet

count decreased to $156 \times 10^9/\text{L}$. Concomitant therapy included glucocorticoids, cyclosporine, methotrexate, and NSAIDs. Thrombocytopenia was not considered serious AE, and unlikely to be the result of tocilizumab therapy. Platelet count returned to normal within a week, without reducing the dose or interrupting the treatment. One patient reported a one-time increase in alkaline phosphatase activity to 6200 IU/L after the first injection of tocilizumab while concomitant therapy included methotrexate and methylprednisolone. This rate returned to normal after eight days without changing the tocilizumab treatment regimen. The AE were considered to be of no significance, and unlikely to be the result of tocilizumab therapy.

While observing clinically significant changes in the vital functions namely, BP and HR, the ECG parameters were also observed. Treatment was not discontinued in any patient due to insufficient therapeutic response of tocilizumab therapy. Normally, the safety profile of tocilizumab in children is quite similar to the safety profile described earlier in adults with rheumatoid arthritis. It was within the expected range for a population of patients receiving immunosuppressive drugs. AE were manifested as mild to moderately severe infections, as well as changes in the laboratory parameters. Deaths did not occur during the period of tocilizumab treatment. No case of discontinuation of therapy was registered due to AE development.

Conclusion

Thus, the results of the annual retrospective observational studies have shown the high efficiency of tocilizumab in patients having the severe systemic variant of JIA, refractory to treatment with glucocorticoids, methotrexate, cyclosporine, combined immunosuppressive

therapy, as well as antiTNF therapy. Therefore, this study shows that tocilizumab induces a remission of both articular symptoms and extra-articular manifestations, while normalizing the laboratory parameters of the disease activity without administering prednisolone *per os*, thus circumventing the development of the severe, irreversible complications of glucocorticoid therapy.

References

- Cassidy JT, Petty RE. Juvenile idiopathic arthritis. In: Cassidy JT, Petty RE, editors. Textbook of pediatric rheumatology, 5th ed. Philadelphia: WB Saunders. 2005.
- Alekseeva EI, Valieva SI, Bzarova TM. Efficacy and safety of repeat courses of rituximab treatment of severe refractory juvenile rheumatoid arthritis. Modern problem of Pediatrics 2009; 8(5):14-25.
- Alekseeva EI, Litvisky PF. Juvenile rheumatoid arthritis. Etiology. Pathogenesis. Clinic. Algorithms for diagnosis and treatment. Guidelines for physicians, teachers, researchers. Under the general editorship of Academician of RAMS, professor AA Baranov. Moscow, 2007.
- Veldhuis GJ, Willemse PHB., Sleijfer DT, van der Graaf WT, Groen HJ, Limburg PC et al. Toxicity and efficacy of escalating dosages of recombinant human interleukin-6 after chemotherapy in patients with breast cancer or non-small-cell lung cancer. J Clin Oncol 1995; 13:2585-2593.
- Rothwell NJ, Busbridge NJ, Lefevre RA, Hardwick AJ. Interleukin-6 is a centrally acting endogenous pyrogen in the rat. Can J Physiol Pharmacol. 1991; 69:1465-1469.
- Castell JV, Gomez-Lechon MJ, David M, Hirano T, Kishimoto T, Heinrich PC. Recombinant human interleukin-6 (IL-6/BSF-2/HSF) regulates the synthesis of acute phase proteins in human hepatocytes. FEBS Lett 1988; 232:347-350.
- Nemeth E, Rivera S, Gabayan V, Keller C, Taudorf S, Pedersen BK et al. IL-6 mediates hypoferrremia of inflammation by inducing the synthesis of the iron regulatory hormone hepcidin. J Clin Invest 2004; 113:1271-1276.
- Ikebuchi K, Wong GG, Clark SC, Ihle JN, Hirai Y, Ogawa M. Interleukin-6 enhancement of interleukin-3-dependent proliferation of multipotential hemopoietic progenitors. Proc Natl Acad Sci USA 1987; 84:9035-9039.
- Kimura H, Ishibashi T, Uchida T, Maruyama Y, Friese P, Burstein SA. Interleukin 6 is a differentiation factor for human megakaryocytes in vitro. Eur. J Immunol 1990; 20:1927-1931.
- Tsigos C, Papanikolaou DA, Defensor R, Mitsiadis CS, Kyrou I, Chrousos G.P. Dose-effects of recombinant human interleukin-6 on pituitary hormone secretion and energy expenditure. Neuroendocrinology 1997; 66:54-62.
- Heliövaara MK, Teppo AM, Karonen SL, Tuominen JA, Ebeling P. Plasma IL-6 concentration is inversely related to insulin sensitivity, and acute phase proteins associate with glucose and lipid metabolism in healthy subjects. Diabetes Obes Metab 2005; 7:729-736.
- Cutolo M, Straub RH. Circadian rhythms in arthritis: hormonal effects on the immune/inflammatory reaction. Autoimmun Rev 2008; 7:223-228.
- Nishimoto N, Kishimoto T. Humanized antihuman IL-6 receptor antibody, tocilizumab. Handb Exp Pharmacol 2008; 181:151-160.
- European Medicines Agency. RoActemra (tocilizumab): summary of product characteristics [online]. Available from URL: <http://www.emea.europa.eu/humandocs/PDFs/EPAR/RoActemra/H-955-PI-en.pdf> [accessed 2009 Mar 23].
- Chugai Pharmaceutical Co. Actemra, a humanized antihuman IL-6 receptor monoclonal antibody obtained approval for indications of rheumatoid arthritis, polyarticular-course juvenile idiopathic arthritis and systemic-onset juvenile idiopathic arthritis [media release]. Available from URL: <http://www.chugai-pharm.co.jp> [accessed 2008 Sep 24].
- Imagawa T, Ozawa R, Miyamae T, Mori M, Nerome Y, Imanaka H et al. Efficacy and safety in 48-week treatment of tocilizumab in children with polyarticular course JIA with polyarticular or oligoarticular onset. Ann. Rheum. Dis. 2007; 66 (Suppl. II): 550.
- Yokota S, Imagawa T, Miyamae T. Safety and efficacy of up to three years of continuous tocilizumab therapy in children with systemic-onset juvenile idiopathic arthritis [SAT0536]. Ann Rheum Dis 2009; 68 (Suppl. 3):715.
- Inaba Y, Aoki C, Ozawa R. Radiologic evaluation of large joints during tocilizumab treatment in children with systemic juvenile idiopathic arthritis [SAT0555]. Ann Rheum Dis 2009; 68(Suppl. 3):720.
- Yokota S, Imagawa T, Mori M, Miyamae T, Aihara Y, Takei S et al. Efficacy and safety of tocilizumab in patients with systemic-onset juvenile idiopathic arthritis: a randomized, double-blind, placebo-controlled, withdrawal phase III trial. Lancet. 2008; 371:998-1006.
- Yokota S, Miyamae T, Imagawa T, Iwata N, Katakura S, Mori M et al. Therapeutic efficacy of humanized recombinant anti-interleukin-6 receptor antibody in children with systemic-onset juvenile idiopathic arthritis. Arthritis Rheum. 2005; 52:818-825.
- Aoki C, Inaba Y, Ozawa R. Effects of tocilizumab

- on radiological findings in polyarticular juvenile idiopathic arthritis [OP-0145]. *Ann Rheum Dis* 2009; 68(Suppl. 3):118.
22. Quartier P, Maire D, Souabni L. Efficacy and safety of tocilizumab in systemic onset juvenile idiopathic arthritis in french centers [FRI0462]. *Ann. Rheum Dis* 2009; 68(Suppl. 3):506.
23. Kaneko U, Imagawa T, Kishi T. Discrepancy between progression of joint damage and improvement of systemic inflammation in patients with systemic-onset juvenile idiopathic arthritis treated with tocilizumab [SAT0548]. *Ann. Rheum Dis* 2009; 68(Suppl.3):719.
24. Giannini EH, Ruperto N, Ravelli A, Lovell DJ, Felson DT, Martini A. Preliminary definition of improvement in juvenile arthritis. *Arthritis Rheum* 1997; 40:1202-1209.
25. Yokota S, Imagawa T, Miyamae T. Safety and efficacy of up to three years of continuous tocilizumab therapy in children with systemic-onset juvenile idiopathic arthritis [SAT0536]. *Ann Rheum Dis* 2009; 68(Suppl. 3):715.