

CLINICAL RESEARCH

Clinical and Morphological Features of Focal Adenomyosis

Aleksey A. Shklyar*; Nina B. Paramonova, PhD; Evgeniya A. Kogan, PhD, ScD; Alexander I. Guus, PhD, ScD; Yuliya B. Kurashvili, PhD, ScD; Leila V. Adamyan, PhD, ScD

*Science Center of obstetrics, gynecology and perinatology named after academician V.I. Kulakov
Moscow, Russian Federation*

Abstract

Background: Adenomyosis is a very real problem encountered in modern gynecology due to the increase in the incidence, severity of the disease, and absence of effective methods of conservative treatment. **The aim** of the study was to investigate the clinical and morphological features of the focal and diffuse forms of adenomyosis.

Methods and Results: The study involved 70 women who applied to the Center with the diagnosis of 'adenomyosis'. Examination included transvaginal sonography (TVS), magnetic resonance spectroscopy (MRS), and morphological study of the adenomyotic foci. With a probability of 99%, one can argue that focal adenomyosis (FA) in its clinical features is different from diffuse adenomyosis (DA) in all its major manifestations.

Conclusion: FA has unique morphological characteristics and clinical features. The diagnosis of FA should be based on a complex of clinical and instrumental data in conjunction with morphological process verification. Besides, there are difficulties in the diagnosis of FA, which is a major reason for the incorrect determination of the treatment tactic for patients. However, the application of MRS allows the preoperative identification of the biochemical structure of the focus and determination of its borders, and in the postoperative period, selection of optimal treatment tactics based on the identified morphological features of the removed adenomyotic foci.

Keywords: focal adenomyosis; transvaginal sonography; magnetic resonance spectroscopy.

Introduction

Adenomyosis is a very real problem encountered in modern gynecology due to the increase in the incidence, severity of the disease, and absence of effective methods of conservative treatment [1].

Adenomyosis is one of the most acute problems in modern gynecology, ranking third in the structure of morbidity, after inflammation and uterine fibroids [2]. Despite the earliest mention of adenomyosis more than 150 years ago, the etiology and pathogenesis of this disease are still unresolved [3]. The nonspecific nature of the symptoms leads to undiagnosed 'adenomyosis' in 88% of cases [1]. Specific data of the clinical manifestations of focal adenomyosis (FA) are virtually absent. There are some references on algomenorrhea in 77% of patients with FA, increase in uterus size, detection of painful nodules, radiating pain in the lumbar region and the rectum, painful

menstruation and heavy bleeding [2,4]. These clinical findings do not differentiate FA from uterine fibroids, and in this connection, there is a high frequency of diagnostic errors. The leading role in the diagnosis is given to morphological studies; however, the accuracy of detection of the heterotopic endometrium does not exceed 70-85%, even in the study of the uterine myometrium post hysterectomy [4,5]. According to the modern classification of adenomyosis, the disease has four stages depending upon the spread of the process; the focal form of adenomyosis is allocated separately [1]. Data on the frequency of occurrence of these forms is relatively few in number. Diffuse adenomyosis (DA) is found in 50-70% of cases of all patients with adenomyosis, and FA occurs rarely in about 3-8% of cases [6,7]. In the most common diffuse form, the uterus is enlarged and globular in shape [8,9]. In FA, a local change in the myometrium is observed, usually on one side of the uterus, caused by its local magnification and resembling pseudo expansions [7,10]. These forms differ histologically, which apparently demonstrate various metabolic activities. Obviously, the various biochemical processes explain the formation of the various forms of adenomyosis and require very different treatment strategies. Data on the morphological features of FA are quite contradictory. Some authors have combined the concept of FA and adenomyoma of the uterus [4,10].

*Corresponding author: Aleksey A. Shklyar, PhD student. Science Center of obstetrics, gynecology and perinatology named after academician V.I. Kulakov. Moscow, Russian Federation.
E-mail: doctorshklyar@gmail.com

The aim of the study was to investigate the clinical and morphological features of the focal and diffuse forms of adenomyosis.

Material and Methods

We examined 70 women. Group 1 consisted of 22 patients with FA; Group 2 included 48 patients with DA. The predominant age of the patients with FA was 30-39 years (36.3%) (subgroup 2); the second largest subgroup included patients between 40-49 years (27.2%) (subgroup 3); patients aged 20-29 years (13.6%) constituted subgroup 1, while patients aged 50-59 years (22.9%) constituted subgroup 4.

The medical history revealed the following complaints: hypermenorrhea, dysmenorrhea, polymenorrhea, scanty discharge from the genital tract in the form of "spotting" before and after menstruation, abdominal pain not associated with menstruation and dyspareunia.

An ultrasound study was performed using a transvaginal probe (Toshiba Aplio XG, SSA-790A) according to standard procedures.

Multi-voxel ¹H-MRS was performed using 2D-CSI - 2D Chemical Shift Imaging. In developing the research methodology of adenomyotic foci, we have identified the optimal parameters of ¹H-MRS: repetition time (TR) of 1500 ms, time to echo (TE) of 135 ms, voxel volume of 1.0-1.5 cm³, the number of voxels (48-64), the number of averages - 4; total scan time of 9-10 min. For a single-voxel MRS, the stimulated echo sequence was used. After the collection of the primary data, post-processing was performed using additional software (Spectroscopy Application), set by the manufacturer (Siemens). In the spectra obtained, the content of the following basic stable metabolites was determined: choline (Cho), creatine (Cr), lactate (Lac).

In subgroup 1, absolute preference was given to less invasive approaches; therefore, laparoscopy and hysteroresectoscopy were applied. In this case, all the patients underwent uterus-conserving surgery, i.e., only the adenomyotic foci were removed. In subgroup 2, for 7 out of the 8 women (87.5%), the preference was also given for the uterus-conserving surgery and the laparoscopic approach remained the method of choice. In subgroup 3, resection of the foci with preservation of the uterus was done in only 2 of the 6 patients (33.3%). In subgroup 4, hysterectomy was performed in all the patients.

Of course, FA was not always decisive in the choice of the surgical technique. In 31.8% of cases, FA was a random finding post hysterectomy; in 36.6% of cases, the focal form itself was the reason for the surgical treatment, and this applied to patients under 40 years of age. In the age group over 40 years, surgical treatment was performed because of the presence of several uterine diseases, of which FA was not a leading pathology. During the surgery, 4.5% foci of the adenomyosis were erroneously regarded as uterine fibroids. Therefore, it is obvious that the early pre-surgery detection of FA would contribute to the uterus-conserving surgery in patients under 40 years of age.

The morphological examination of the adenomyotic lesions included macroscopic and microscopic studies with tissue fixation in 10% neutral formalin and staining of the paraffin sections with hematoxylin and eosin.

Results were statistically processed using the software package Statistica 6.1 for Windows.

Results

It was found that the most common complaints among patients with FA were abdominal pain and menstrual dysfunction mainly due to a type of polymenorrhea. The duration of menses was 4-8 (± 3.5) days for a menstrual cycle of 25-35 (± 7) days. The average age of menarche was 14 ± 3 years. According to the women's estimates, menstrual bleeding was abundant in 72.7% of the patients, moderate in 22.7% of cases, and meager in 4.5% of cases. Menstruation was very painful requiring NSAIDs in 40.9% of cases. Another 13.6% of patients estimated menstruation as moderately painful, while 45.5% of women did not experience any pain during menstruation. In subgroup 2, in patients with DA, the commonest complaints were hypermenorrhea in 41 (85.4%) women, dysmenorrhea in 36 (75.0%) women, polymenorrhea in 33 (68.7%) women, scanty blood discharge in the form of "spotting" in 20 (41.6%) women, a constant pain in the lower abdomen, not related to the menstrual cycle, in 21 (43.7%) women, and dyspareunia in 13 (27.0%) women.

The reproductive history was studied in detail in the 22 patients with FA. Thus, infertility I was noted in 8 (36.3%) women and infertility II in 3 (13.6%) patients. Natural pregnancy was noted in 13 (59%) women. IVF procedure was in the anamnesis of one (4.5%) woman. A spontaneous miscarriage occurred in 4 (18.1%) patients and abortion at short periods of pregnancy by personal preference in 10 (45.4%) women. In patients with DA, infertility I or II occurred in 33.3% of the cases, spontaneous miscarriage in anamnesis was in 62.5% patients, whereas natural pregnancy was observed in 46 (95.8%) patients.

Functional diagnosis of focal adenomyosis

In most cases, the diagnosis of adenomyosis was based on the set of histological signs visible after resection of the uterine or hysterectomy. The rate of the preoperative diagnosis based on clinical findings is poor, ranging from 2.6% to 26% [11], despite the high sensitivity of TVS and MRI (88%-100%) at their relatively low specificity [12]. According to M. Levgur, who reviewed the available literature for 56 years (1949-2005), the sensitivity of the ultrasonic method in the diagnosis of adenomyosis ranges from 50 to 87% [13].

Based on TVS, FA was diagnosed in only 31.8% of the patients, while in 40.9% of patients the adenomyotic foci had been mistaken for uterine fibroids. The adenomyotic foci were not detected in 27.3% of cases; according to the ultrasonic examination, in half of the cases (3 of the 6 patients), the nodule was mistaken as a description of DA; in the other half of the cases (3 of the 6 patients), the myometrium was described without pathological changes (Fig.1).

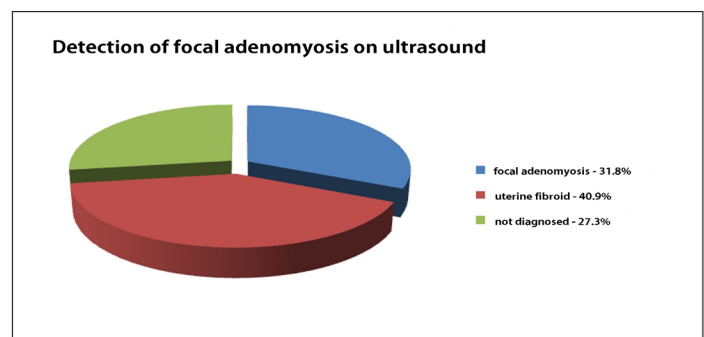


Figure 1

Thus, the preoperative diagnosis of FA was not always successful. The MRI findings, however, enabled the FA to be revealed more frequently [14,15].

The size of the adenomyotic foci ranged from 1.5 to 5.4 cm (3.15 ± 1.2 cm). The foci were mainly located intermuscularly; also, they were located in the interstitial-subserous layer in 5 patients and submucosally in 7 women. Multiple adenomyotic foci were found in one case.

The anteroposterior diameter of the uterus was 5.6 ± 1.1 cm, with the difference in thickness between the anterior and posterior walls being 1.85 ± 1.07 cm (Fig.2 and 3).

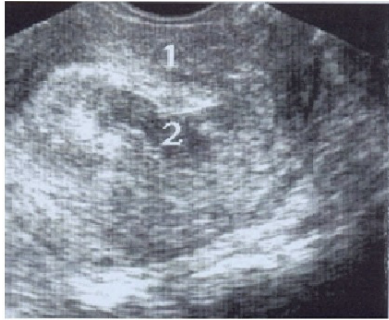

Figure 2.

FA. Transvaginal sonography in the longitudinal plane.

1- Uterus;
2- Hyperintense cystic lesion.

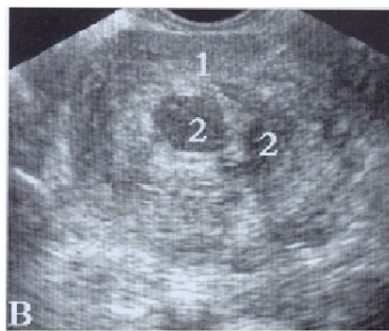

Figure 3.

FA. Transvaginal sonography in the transverse plane.

1- Uterus;
2- Hyperintense cystic lesions.

MRS of the nodules was performed in 9 of the 22 patients with FA. Adenomyotic foci reached a diameter of 50-90 mm in size.

The spectra obtained were characterized by the content of the following basic stable metabolites: choline (Cho) - a component of the phospholipid metabolism, a cell membrane marker reflecting cell proliferation; creatine - a marker of the aerobic metabolism; lactate (Lac) - an end-product of anaerobic glycolysis (not detected in normal tissue). A choline peak “++” was present in 7 (77.8%) patients, “+” in 2 (22.3%) patients. A creatine peak was observed in 7 (77.8%) patients: “+ +” in 4 patients, “+” in 3 patients. A lactate peak “+” was seen in 1 (11.1%) patient while the remaining patients were negative. A lipid peak “+ +” was observed in 3 (33.3%) patients and “+” was seen in 1 (11.1%) patient.

The morphological examination of the adenomyotic lesions included macroscopic and microscopic studies with tissue fixation in 10% neutral formalin and staining of the paraffin sections with hematoxylin and eosin. The histological activity of the adenomyosis centers was evaluated according to our data [5].

Histological examination of the adenomyotic foci the presence foci of the ectopic endometrium combined with hyperplastic and hypertrophic myometrium, while on the

periphery, the nodule was surrounded by the intact myocytes; in contrast to the fibroid of the uterus, the adenomyotic nodule did not have a clear capsule. The foci of the adenomyosis were identified as active, inactive and combined. The active lesions were the endometrioid heterotopias with large, tortuous and straight glands. Glands had a high columnar epithelium with oval nuclei located at different levels with multiple mitoses. We determined the ciliated cells, visible as a secretory transformation in some places. Loose stroma was seen consisting of fibroblast-like cells with oval and round nuclei and the spiral arteries and venules with the swollen endothelium. Inactive foci of adenomyosis were present with straight glands with a narrow lumen; sometimes the cystic dilated glands were also encountered. In the inactive foci, cuboidal as well as flattened epithelium was detected. The stroma was compact with small-cell fibers; occasionally, a small number of vessels were present. In the combined variant of FA, the active and inactive lesions occurred in the same sample. In all the variants, the adenomyotic foci were surrounded by the bundles of the hypertrophied and hyperplastic smooth muscle cells with the formation of concentric structures.

Discussion

According to the findings obtained (Fig.4), the pain in the abdomen predominated over the abundant menstrual bleeding in the NA patients. However, the main complaint for seeking medical attention was dysmenorrhea, which occurred both in the cases of diffuse and focal adenomyosis. With a probability of 99%, one can argue that focal adenomyosis (FA) in its clinical features is different from diffuse adenomyosis (DA) in all its major manifestations.

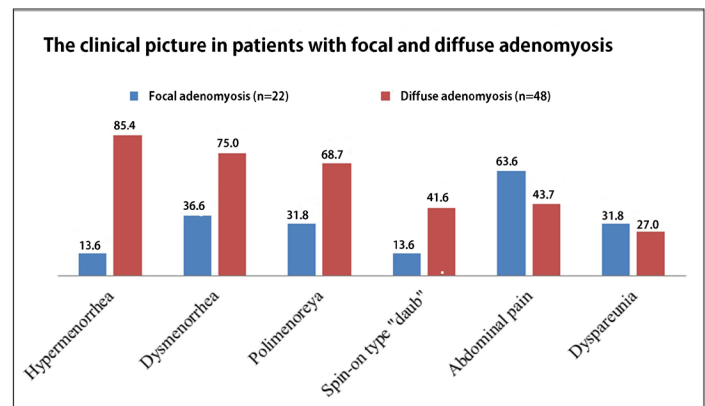


Figure 4

Based on the data from the reproductive history, the patients with FA compared with DA were more likely to suffer from infertility; they rarely had the natural pregnancy and loss due to miscarriage.

The analysis of all the ultrasound images revealed the most typical features of FA:

- hyperechoic areas (round or oval shape) within the myometrium with small anechoic inclusions (0.2-0.6 cm in diameter) or cystic cavities of 0.7-3.3 cm in diameter, containing a finely divided suspension (Fig.2 and 3);
- smooth and not always clear-cut contours of the foci (60%);
- hyperechogenicity next to the anterior contours of the foci and hypoechogenicity next to posterior contours of foci (58.3%);

- the presence in pathological focus of closely spaced strips of the medium and low echogenicity, directed perpendicular to the scanning cavity (33.3%).

According to the MRS, the adenomyotic foci in most cases revealed choline, creatine, and lipid peaks. The choline peak is caused by the solid structure of the lesion and the biochemical activity of the membranes. The absence of the lactate peak reflects anaerobic glycolysis and indicates the presence of benign tumors. The lipid peak indicates the presence of fatty acids in the adenomyotic foci typical for necrosis; however, the reason for increasing the concentration of lipids in the adenomyotic foci requires clarification.

Thus, FA has unique morphological characteristics and clinical features. The diagnosis of FA should be based on a complex of clinical and instrumental data in conjunction with morphological process verification. Besides, there are difficulties in the diagnosis of FA, which is a major reason for the incorrect determination of the treatment tactic for patients. However, the application of MRS allows the preoperative identification of the biochemical structure of the focus and determination of its borders, and in the postoperative period, selection of optimal treatment tactics based on the identified morphological features of the removed adenomyotic foci. Our results warrant further study for better understanding this medical condition.

References

1. Adamyan LV, Kulakov VI. Endometriosis. Moscow; Medicine; 2006. [Book in Russian].
2. Viganò P, Parazzini F, Somigliana E, Vercillini P. Endometriosis: epidemiology and aetiological factors. *Best Pract Res Clin Obstet Gynecol* 2004; 18(2):177-200.
3. Giudice LC, Evers JLH, Healy DL. Endometriosis: Science and Practice. Oxford: Wiley-Blackwell; 2012.
4. Levy G, Dehaene A, Laurent N, Lernout M, Collinet P, Lucot JP, et al. An update on adenomyosis. *Diagn Interv Imaging* 2013; 94(1):3-25.
5. Kogan EA, Nizyaeva NV, Demura TA, Ejova LS, Unanyan AL. Morphological and immunohistochemical characteristics of adenomyosis in combination with endometrial adenocarcinoma. *Arkh Patol* 2010; 4:7-12. [Article in Russian].
6. Damirov MM. Adenomyosis: clinical manifestations, diagnosis, treatment. Tver, 2002. [Book in Russian].
7. Baskakov VI, Tsvelev SE, Cyra EP. Endometrial disease. St. Petersburg: Neva-Lux; 2002. [Book in Russian].
8. Kurman RJ, Ellenson LH, Ronnett BM. Blaustein's Pathology of the Female Genital Tract. Sixth Edition. Springer; 2011.
9. Robboy SJ, Mutter GL, Prat J, Bentley R, Russel P, Anderson M. Pathology of the female reproductive tract. 2nd edition; London: Elsevier (Churchill Livingstone); 2009.
10. Nucci MR, Oliva E. Gynecologic Pathology. Philadelphia: Elsevier (Churchill Livingstone); 2009.
11. Anichkov NM, Pechenikova VA, Kostyuchek DF. Clinical and morphological features of endometrial disease: adenomyosis, ovarian endometriosis, ovarian, extragenital endometriosis. *Arkh Patol* 2011; 4:5-10. [Article in Russian].
12. Sammour A, Pirwany I, Usubutun A, Arseneau J, Tulandi T. Correlations between extent and spread of adenomyosis and clinical symptoms. *Gynecol Obstet Invest* 2002; 54(4):213-6.
13. Levгур M. Diagnosis of adenomyosis: a review J

Reprod Med 2007; 52(3):177-193.

14. Dueholm M, Lundorf E. Transvaginal ultrasound or MRI for diagnosis of adenomyosis. *Curr Opin Obstet Gynecol* 2007; 19(6):505-12.

15. Champaneria R, Abedin P, Daniels J, Balogun M, Khan KS. Ultrasound scan and magnetic resonance imaging for the diagnosis of adenomyosis: systematic review comparing test accuracy. *Acta Obstet Gynecol Scand* 2010 ; 89(11):1374-84.