

Carotid Web in Elderly Patient with Recurrent Ischemic Stroke: A Case Report

Adel Alzahrani^{1*}, Faisal Alghamdi¹, Meshari Alzahrani¹, Jumanah Ardawi¹, Fatima Altalhi¹,
Mahammad Bokhary¹, Mohammad Shebly¹

¹Department of Radiology and Medical Imaging, King Abdullah Medical City, Makkah, Saudi Arabia

Abstract

Background: A carotid web is a focal, shelf-like fibroelastic intimal protrusion in the proximal internal carotid artery, regarded as a variant of intimal fibromuscular dysplasia. It disrupts normal laminar flow, creating areas of stasis that predispose to thrombus formation and distal embolization, and is increasingly recognised as a cause of cryptogenic ischemic stroke, particularly in young and middle-aged adults without conventional vascular risk factors.

Case Presentation: A 61-year-old male with multiple vascular risk factors and a history of right-sided ischemic stroke who presented with recurrent transient left-sided weakness. CT angiography was limited by motion artefact, preventing accurate assessment. Subsequent duplex ultrasound revealed a characteristic echogenic shelf-like projection at the posterior wall of the right carotid bulb consistent with a carotid web. In view of recurrent ischemic symptoms, the patient underwent successful carotid artery stenting with restoration of normal flow dynamics.

Conclusion: This case emphasises the importance of multimodality vascular imaging and heightened clinical suspicion for carotid web in patients presenting with recurrent embolic events and minimal atherosclerosis. Early recognition and definitive intervention are essential to prevent recurrent cerebrovascular episodes. (**International Journal of Biomedicine. 2026;16(2):270-273.**)

Keywords: carotid web • embolic stroke • carotid artery stenting • duplex ultrasound • CT angiography • fibromuscular dysplasia

For citation: Alzahrani A, Alghamdi F, Alzahrani M, Ardawi J, Altalhi F, Bokhary M, Shebly M. Carotid Web in Elderly Patient with Recurrent Ischemic Stroke: A Case Report. International Journal of Biomedicine. 2026;16(2):270-273. doi:10.21103/Article16(2)_CR2

Introduction

Carotid web is a rare, focal intimal variant of fibromuscular dysplasia (FMD) that predominantly involves the proximal internal carotid artery at the carotid bulb. Morphologically, it is characterized by a thin, shelf-like membranous projection that extends into the arterial lumen. Histopathologically, carotid webs are characterized as a distinct, non-atherosclerotic vascular pathology consisting of focal fibroelastic thickening of the arterial intima. Although uncommon, carotid webs are increasingly recognized as an etiology of cryptogenic and recurrent embolic ischemic strokes, particularly in younger adults and in patients lacking conventional cardiovascular risk factors.^{1,2}

The pathophysiological mechanism underlying stroke in carotid webs is primarily artery-to-artery thromboembolism. The protruding intimal shelf alters normal laminar flow, generating localized regions of flow separation, low shear stress, and blood stasis, which predispose to thrombus formation on the web surface. Embolization of these thrombi can result in distal cerebral ischemia, often leading to recurrent strokes in the ipsilateral vascular territory. Unlike atherosclerotic stenosis, carotid webs frequently cause ischemic events without significant luminal narrowing, highlighting the importance of flow dynamics rather than occlusion per se in their clinical significance.³

Despite growing awareness, carotid web remains underdiagnosed, partly because of its subtle radiologic appearance and potential to be misinterpreted as a noncalcified atherosclerotic plaque, intimal dissection, or intraluminal thrombus. The development and widespread use of high-resolution imaging modalities, including computed tomography

*Corresponding author: Adel Alzahrani. E-mail: adel.alzahrani14@alumni.imperial.ac.uk

angiography (CTA), magnetic resonance angiography (MRA), and duplex ultrasonography, have significantly improved the detection and characterization of these lesions.⁴ CTA, in particular, provides excellent spatial resolution and allows visualization of the thin, membranous shelf that defines the web, while duplex ultrasonography can detect hemodynamic disturbances and intimal protrusions.

Management of carotid web remains controversial, with options ranging from antiplatelet therapy for secondary stroke prevention to surgical or endovascular interventions. Carotid endarterectomy (CEA) and carotid artery stenting (CAS) have been reported as effective strategies, particularly in patients with recurrent ischemic events despite medical therapy. Long-term outcomes remain under investigation, and consensus guidelines for management are lacking due to the rarity of the condition and the limited number of available studies.^{5,6}

Herein, we report a case of a 61-year-old man with recurrent ischemic events attributable to a carotid web, successfully treated with CAS. We also provide a comprehensive review of current evidence regarding pathophysiology, diagnostic evaluation, and therapeutic strategies for this underrecognized but clinically significant vascular abnormality.

Case Presentation

A 61-year-old male with a medical history of diabetes mellitus, hypertension, ischemic heart disease, and prior percutaneous coronary intervention presented for evaluation of suspected carotid artery stenosis. He had a previous right-sided ischemic stroke resulting in residual right hemiparesis. Two months before presentation, he experienced an episode of left-sided weakness and slurred speech that improved with medical therapy and physiotherapy. Recurrent symptoms prompted further vascular assessment.

Vital Signs and Laboratory Investigations

On admission, vital signs were stable (HR - 90 bpm, BP - 114/54 mmHg, RR - 16). Laboratory values, including liver enzymes, renal parameters, albumin, and coagulation profile, were within normal limits (Table 1). ECG demonstrated a sinus rhythm.

Table 1.

Basic laboratory parameters

Parameter	Result	Reference Range	Interpretation
ALT	8 U/L	0–55 U/L	Normal
AST	17 U/L	8–48 U/L	Normal
Albumin	4.3 g/dL	3.2–4.6 g/dL	Normal
BUN	16 mg/dL	8–24 mg/dL	Normal
BNP	15.6 pg/mL	0–380 pg/mL	Normal

CT Angiography

CTA of the neck was performed, but the CTA exam was substantially degraded by motion artefact, limiting diagnostic clarity (Figure 1). Chronic occlusion of the right MCA distal M1 segment with collateral formation was observed. Irregularities in the left MCA and bilateral PCAs were noted, but suspected luminal narrowing at the distal right common carotid artery could not be conclusively assessed.

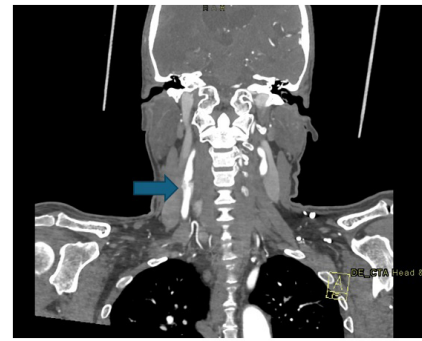


Figure 1. CT angiography of the neck showing a motion-degraded image with suspected luminal narrowing at the origin of the right distal common carotid artery (arrow).

Carotid Duplex Ultrasound

Duplex ultrasound demonstrated a thin, echogenic, shelf-like intraluminal projection arising from the posterior wall of the right carotid bulb and extending into the internal carotid artery, producing local turbulence on color Doppler imaging (Figure 2). These findings were characteristic of a carotid web.

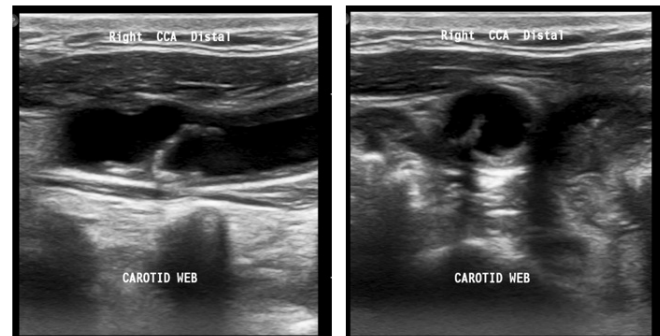


Figure 2. Longitudinal (left) and transverse (right) distal common carotid ultrasound showing a shelf-like intraluminal projection at the posterior wall of the carotid bulb (arrow), consistent with carotid web.

Intervention

Given the patient's recurrent ischemic episodes and supportive imaging, a multidisciplinary team recommended carotid artery stenting. The procedure was performed under local anesthesia, resulting in complete stent expansion and restoration of laminar flow. He experienced no postoperative complications and was discharged on dual antiplatelet therapy with scheduled follow-up imaging.

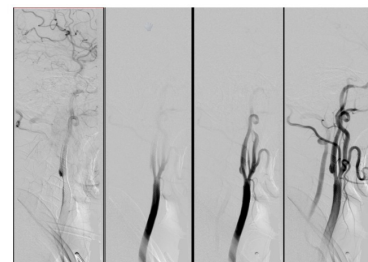


Figure 3. Digital subtraction angiography (DSA) during carotid stenting demonstrates complete stent expansion, accompanied by restoration of laminar flow in the right internal carotid artery.

Discussion

This case highlights several clinically important points. First, the carotid web should be actively considered in patients with recurrent embolic stroke, especially when traditional risk factors or high-grade stenosis are absent. Secondly, CTA remains the most powerful non-invasive tool, but its diagnostic accuracy depends on image quality, whilst Duplex ultrasound plays a critical complementary role, particularly when CTA findings are limited. Furthermore, early definitive intervention is essential, as reliance on medical therapy alone exposes patients to substantial risk of stroke recurrence. Lastly, CAS represents safe, durable, and effective treatment, particularly for older patients or those with complex anatomies.

Carotid web is an intimal variant of fibromuscular dysplasia increasingly recognized as an important but frequently underdiagnosed cause of recurrent embolic stroke.^{1,3,7,13,14} Although historically described in young female patients without traditional vascular risk factors, emerging data suggest the condition spans a wider age range and may be encountered in individuals with vascular comorbidities, as seen in this case.² This growing awareness underscores the need for heightened diagnostic vigilance, particularly in patients with recurrent ischemic events despite minimal atherosclerotic burden.

Histopathologically, the carotid web represents focal intimal fibroplasia, distinct from the medial fibroplasia typical of systemic FMD.² The shelf-like protrusion arising from the posterior wall of the carotid bulb creates a region of geometric stenosis without the plaque features associated with atherosclerosis. High-resolution imaging and computational fluid dynamics analyses reveal that this structural anomaly produces disturbed laminar flow, with a characteristic vortex and zone of recirculation distal to the web.⁸ This area of low shear stress is highly thrombogenic, predisposing to fibrin-rich mural thrombus formation and subsequent artery-to-artery embolization. Importantly, this mechanism explains why many patients with carotid web suffer recurrent strokes despite the absence of high-grade stenosis or plaque vulnerability factors.

Accurate diagnosis remains challenging because carotid webs can mimic atherosclerotic plaque, dissection flaps, intraluminal thrombus, or even imaging artefacts.^{3,10,12} CTA is generally considered the preferred initial modality due to its high spatial resolution and ability to visualize thin intraluminal projections.^{4,11} However, motion artefacts, suboptimal arterial opacification, or inadequate multiplanar reconstruction can obscure the lesion, as demonstrated in this case.

Duplex ultrasound, although operator-dependent, can provide valuable supportive evidence by demonstrating the echogenic intraluminal projection and associated turbulent flow patterns.¹¹ The sensitivity of duplex imaging is enhanced when combined with color Doppler and angle-adjusted spectral analysis. Digital subtraction angiography remains the definitive modality, offering superior spatial and temporal resolution and enabling dynamic assessment of flow patterns necessary for procedural planning.^{6,15}

Given the complementary strengths of each modality, a multimodal imaging approach is often required to increase diagnostic confidence and avoid misclassification.

Although medical therapy with antiplatelet or anticoagulation agents appears reasonable in theory, multiple retrospective cohorts show that recurrent ischemic events remain common when carotid webs are managed conservatively.^{2,14} This supports the concept that the lesion's embolic potential is primarily driven by abnormal flow dynamics rather than platelet activation alone.

Definitive mechanical exclusion of the web via carotid endarterectomy (CEA) or carotid artery stenting (CAS) has been associated with excellent clinical outcomes, low complication rates, and near-elimination of recurrence risk.^{5,16-19} CAS, as demonstrated in this case, is minimally invasive, avoids cranial nerve injury risk associated with CEA, and reliably restores laminar flow across the affected segment. Long-term follow-up studies demonstrate durable patency, low restenosis risk, and sustained absence of recurrent stroke after stenting for carotid web.^{15,18}

Conclusion

Carotid web is an important but frequently under-recognized cause of recurrent embolic ischemic stroke. Its subtle imaging characteristics and tendency to mimic other vascular pathologies contribute to diagnostic difficulty. This case illustrates the value of duplex ultrasound when CTA is inconclusive and supports carotid artery stenting as an effective and durable treatment option. Early identification and intervention are essential for preventing recurrent cerebrovascular events and improving long-term neurologic outcomes.

Author Contributions

Adel Alzahrani: Supervision, Writing – review and editing.
Faisal Alghamdi: Data interpretation, Writing – original draft.
Meshari Alzahrani: Data curation, Writing – original draft.
Jumana Aradhawi: Writing – original draft.
Fatima Altalhi: Resources, Writing – original draft.
Mohammad Bokhari: Data curation, Writing – original draft.
Mohammad Shably: Data analysis, Writing – original draft.
 All authors have approved the final article.

Conflicts of Interest

The authors have declared no conflict of interest.

References

- Choi PM, Singh D, Trivedi A, Qazi E, George D, Wong J, Demchuk AM, Goyal M, Hill MD, Menon BK. Carotid Webs and Recurrent Ischemic Strokes in the Era of CT Angiography. *AJNR Am J Neuroradiol.* 2015 Nov;36(11):2134-9. doi: 10.3174/ajnr.A4431. Epub 2015 Jul 30. PMID: 26228877; PMCID: PMC7964886.
- Haussen DC, Grossberg JA, Bouslama M, Pradilla G, Belagaje S, Bianchi N, Allen JW, Frankel M, Nogueira RG. Carotid Web (Intimal Fibromuscular Dysplasia) Has High Stroke Recurrence Risk and Is Amenable to Stenting.

- Stroke. 2017 Nov;48(11):3134-3137. doi: 10.1161/STROKEAHA.117.019020. Epub 2017 Oct 10. PMID: 29018133.
3. Coutinho JM, Derkatch S, Potvin AR, Tomlinson G, Casaubon LK, Silver FL, Mandell DM. Carotid artery web and ischemic stroke: A case-control study. *Neurology*. 2017 Jan 3;88(1):65-69. doi: 10.1212/WNL.0000000000003464. Epub 2016 Nov 18. Erratum in: *Neurology*. 2017 Aug 1;89(5):521. doi: 10.1212/WNL.0000000000004167. PMID: 27864523; PMCID: PMC5200857.
4. Kim SJ, Nogueira RG, Haussen DC. Current Understanding and Gaps in Research of Carotid Webs in Ischemic Strokes: A Review. *JAMA Neurol*. 2019 Mar 1;76(3):355-361. doi: 10.1001/jamaneurol.2018.3366. PMID: 30398546.
5. Zhang AJ, Dhruv P, Choi P, Bakker C, Koffel J, Anderson D, Kim J, Jagadeesan B, Menon BK, Streib C. A Systematic Literature Review of Patients With Carotid Web and Acute Ischemic Stroke. *Stroke*. 2018 Dec;49(12):2872-2876. doi: 10.1161/STROKEAHA.118.021907. PMID: 30571430.
6. Pasarikovski CR, Lynch J, Corrin M, Ku JC, Kumar A, Pereira VM, Krings T, da Costa L, Black SE, Agid R, Yang VX. Carotid stenting for symptomatic carotid artery web: Multicenter experience. *Interv Neuroradiol*. 2024 Jan 17:15910199231226293. doi: 10.1177/15910199231226293. Epub ahead of print. PMID: 38233047; PMCID: PMC11569737.
7. Chen H, Colasurdo M, Costa M, Nossek E, Kan P. Carotid webs: a review of pathophysiology, diagnostic findings, and treatment options. *J Neurointerv Surg*. 2024 Nov 22;16(12):1294-1298. doi: 10.1136/jnis-2023-021243.
8. Compagne KCJ, Dilba K, Postema EJ, van Es ACGM, Emmer BJ, Majoie CBLM, van Zwam WH, Dippel DWJ, Wentzel JJ, van der Lugt A, Gijzen FJH; MR CLEAN investigators. Flow Patterns in Carotid Webs: A Patient-Based Computational Fluid Dynamics Study. *AJNR Am J Neuroradiol*. 2019 Apr;40(4):703-708. doi: 10.3174/ajnr.A6012. Epub 2019 Mar 14. PMID: 30872422.
9. Landzberg D, Nogueira RG, Al-Bayati AR, Kim SJ, Bouslama M, Pisani L, da Camara CP, Frankel M, Nahab FB, Bianchi N, Haussen DC. Baseline Characteristics of Patients with Symptomatic Carotid Webs: A Matched Case Control Study. *J Stroke Cerebrovasc Dis*. 2021 Aug;30(8):105823. doi: 10.1016/j.jstrokecerebrovasdis.2021.105823. Epub 2021 May 23. PMID: 34034127.
10. Guillon B, Lévy C, Bousser MG. Internal carotid artery dissection: an update. *J Neurol Sci*. 1998 Jan 8;153(2):146-58. doi: 10.1016/s0022-510x(97)00287-6. PMID: 9511874.
11. Liang S, Qin P, Xie L, Niu S, Luo J, Chen F, Chen X, Zhang J, Wang G. The carotid web: Current research status and imaging features. *Front Neurosci*. 2023 Feb 13;17:1104212. doi: 10.3389/fnins.2023.1104212. PMID: 36860618; PMCID: PMC9968728.
12. Coutinho JM, Derkatch S, Potvin AR, Tomlinson G, Casaubon LK, Silver FL, Mandell DM. Carotid artery web and ischemic stroke: A case-control study. *Neurology*. 2017 Jan 3;88(1):65-69. doi: 10.1212/WNL.0000000000003464. Epub 2016 Nov 18. Erratum in: *Neurology*. 2017 Aug 1;89(5):521. doi: 10.1212/WNL.0000000000004167. PMID: 27864523; PMCID: PMC5200857.
13. Joux J, Boulanger M, Jeannin S, Chausson N, Hennequin JL, Molinié V, Smadja D, Touzé E, Olindo S. Association Between Carotid Bulb Diaphragm and Ischemic Stroke in Young Afro-Caribbean Patients: A Population-Based Case-Control Study. *Stroke*. 2016 Oct;47(10):2641-4. doi: 10.1161/STROKEAHA.116.013918. Epub 2016 Sep 13. PMID: 27625379.
14. Sajedi PI, Gonzalez JN, Cronin CA, Kouo T, Steven A, Zhuo J, Thompson O, Castellani R, Kittner SJ, Gandhi D, Raghavan P. Carotid Bulb Webs as a Cause of "Cryptogenic" Ischemic Stroke. *AJNR Am J Neuroradiol*. 2017 Jul;38(7):1399-1404. doi: 10.3174/ajnr.A5208. Epub 2017 May 11. PMID: 28495950; PMCID: PMC7959897.
15. Bounajem MT, Liang A, Trang A, El Baba B, Bielinski TM, Sangwon K, Zhang Y, Wiggan D, Grin E, Gajjar A, Pasarikovski CR, Yang VX, Agid R, Levitt M, Anderson M, Meyer RM, Cherian J, Howard B, Hendrix P, Abecassis IJ, Srinivasan V, El Naamani K, Gooch MR, Nossek E, Grandhi R. Outcomes after carotid revascularization for symptomatic carotid artery web: A multi-institutional cohort study. *Interv Neuroradiol*. 2025 Aug 8:15910199251365529. doi: 10.1177/15910199251365529. Epub ahead of print. PMID: 40776764; PMCID: PMC12334411.
16. Wojcik K, Milburn J, Vidal G, Tarsia J, Steven A. Survey of Current Management Practices for Carotid Webs. *Ochsner J*. 2019 Winter;19(4):296-302. doi: 10.31486/toj.18.0114. PMID: 31903051; PMCID: PMC6928665.
17. DaCosta M, Tadi P, Surowiec SM. Carotid Endarterectomy. 2023 Jul 24. In: *StatPearls [Internet]*. Treasure Island (FL): StatPearls Publishing; 2026 Jan-. PMID: 29261917.
18. Kumar R, Chadha D, Chaddha A, Chauhan R, Singh N, Kamal P, Mishra A, Kaur N. The Safety and Long-Term Efficacy of Carotid Artery Stenting: An All-Comers Registry. *Cureus*. 2022 Nov 30;14(11):e32060. doi: 10.7759/cureus.32060. PMID: 36600837; PMCID: PMC9800945.
19. Trystuła M, Tomaszewski T, Pačalska M. Health-related quality of life in ischaemic stroke survivors after carotid endarterectomy (CEA) and carotid artery stenting (CAS): confounder-controlled analysis. *Postepy Kardiol Interwencyjne*. 2019;15(2):226-233. doi: 10.5114/aic.2019.84441. Epub 2019 Apr 13. PMID: 31497056.